

# HCV-related cryoglobulinemic glomerulonephritis: implications of antiviral and immunosuppressive therapies

*Giovanni Garini, Landino Allegri, Francesco Iannuzzella, Augusto Vaglio, Carlo Buzio*

Department of Internal Medicine, Nephrology and Health Sciences, University of Parma, Parma, Italy

**Abstract.** The most frequent renal involvement in patients with chronic hepatitis C virus (HCV) infection is cryoglobulinemic glomerulonephritis, with type I membranoproliferative glomerulonephritis (MPGN) being the predominant histological pattern. The pathogenesis of HCV-related cryoglobulinemic MPGN is unknown, but the glomerular damage may be due to the deposition of immune complexes of HCV, IgG, and IgM rheumatoid factors. Clinically, cryoglobulinemic MPGN may range from isolated proteinuria to overt nephritic or nephrotic syndrome, with variable progression to chronic renal insufficiency. The management of cryoglobulinemic MPGN is difficult; the eradication of HCV by means of antiviral therapy (peginterferon plus ribavirin) leads to clinical remission in a proportion of patients, but severe renal disease may be resistant to antiviral therapy. In such cases, corticosteroids and immunosuppressive agents have been used to decrease cryoglobulin production and improve the vasculitic manifestations, but long-lasting remission of the renal disease is uncommon. Here we describe four patients with HCV-related cryoglobulinemic MPGN and the strategies used for their management. The principal message provided by these illustrative cases is that antiviral therapy alone can be the first-line treatment for patients with mild-to-moderate kidney involvement, whereas a short-term course of corticosteroids and cytotoxic agents followed by antiviral therapy may be a reasonable therapeutic strategy for patients with severe/active renal disease. ([www.actabiomedica.it](http://www.actabiomedica.it))

**Key words:** Hepatitis C virus, mixed cryoglobulinemia, membranoproliferative glomerulonephritis, interferon- $\alpha$ , ribavirin, rituximab

## Introduction

Hepatitis C virus (HCV) is a leading cause of chronic liver disease in the Western world and may also be associated with a number of extra-hepatic disorders, the most important of which are mixed cryoglobulinemia and glomerulonephritis (1).

Mixed cryoglobulins (MCs) are immune complexes of mono- or polyclonal IgM that share rheumatoid factor (RF) activity and bind to polyclonal IgGs; they are categorised as type II if the IgM RF is monoclonal, and type III if it is polyclonal (2). Unusual MCs consisting of oligoclonal IgM RF and polyclonal IgG have been detected and called type II-type III variant (3), a serologic subset which is considered

an intermediate transitional process from type III (polyclonal) to type II (monoclonal) MCs.

HCV has been recognised as the main etiologic factor of MCs (4,5,6) since its discovery in 1989 (7), and now accounts for 73% of all forms of cryoglobulinemia (8). Circulating cryoglobulins can be detected in more than 50% of HCV-infected patients (9,10), but the mechanism leading to MC overproduction during HCV-infection remains unclear. A possible causal link between chronic HCV infection and MC is the finding that peripheral B-cells infected with HCV are clonally expanded and activated to secrete IgM molecules with RF activity (6, 11-13). The recent identification of CD81 as one of the HCV receptor candidates on B-lymphocytes provides a mechanism

by which these cells are infected and activated by the virus (14).

The majority of HCV-infected patients with cryoglobulinemia are asymptomatic or have non-specific findings, the main clinical manifestations being palpable purpura, weakness, and arthralgias (8-10, 15, 16). Cryoglobulinemic vasculitis involving small and medium-sized arteries, capillaries, and venules is observed in less than 10% of patients (17), the most frequently affected organs being the skin (leg ulcers), nerves (peripheral neuropathy) and kidneys (glomerulonephritis).

Renal involvement occurs in one-third of cryoglobulinemic patients and is almost exclusively associated with type II MCs (18-20). The main type of glomerulopathy associated with HCV-related cryoglobulinemia is membranoproliferative glomerulonephritis (MPGN) with subendothelial immune deposits showing the classic cryoglobulin-like structure (18, 19, 21, 22). Clinically, cryoglobulinemic glomerulonephritis (CGN) may range from isolated proteinuria to overt nephritic (20-30%) or nephrotic syndrome (20%), with variable progression to chronic renal insufficiency (18, 23). Although end-stage renal failure requiring dialysis is rare (about 10% of cases), patients with CGN have a poor prognosis because of the unusually high incidence of infections and cardiovascular disease (23, 24).

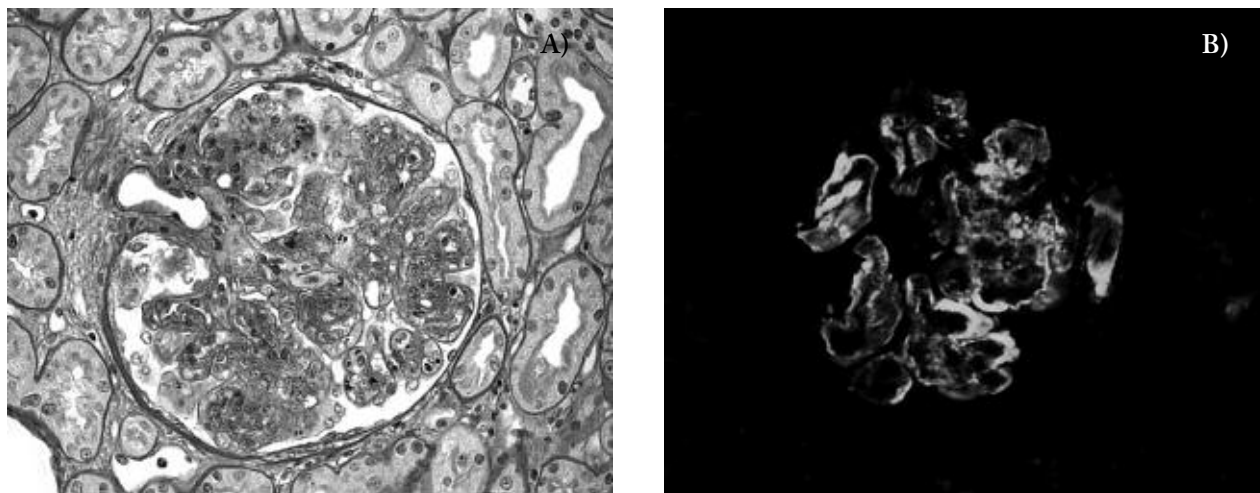
Current evidence of the direct role of HCV in the pathogenesis of cryoglobulinemic CGN has prompted the use of antiviral therapy. Complete CGN remission has been observed in anecdotal cases treated with interferon- $\alpha$  (IFN- $\alpha$ ) alone or combined with ribavirin (25-31), but non-responses or relapses after IFN- $\alpha$  discontinuation are frequent. Furthermore, IFN- $\alpha$  may be inadequate or even harmful in patients with systemic vasculitis and active renal disease (32-34). In such cases, corticosteroids and immunosuppressive agents have been used to decrease cryoglobulin production and improve vasculitic manifestations, but long-lasting remission of the renal disease is uncommon.

The treatment of cryoglobulinemia and glomerulonephritis associated with HCV infection is problematic because of the multifactorial origin and clinical variability of the syndrome. Here we describe four patients with HCV-related cryoglobulinemic MPGN and the strategies used for their management.

## Case reports

### Case 1

A 66-year-old woman with a 5-year history of arthralgia and purpura was admitted to our Department for the evaluation of a nephrotic syndrome. Physical examination revealed ankle edema, palpable purpura of the legs and hypertension (170/100 mmHg). The laboratory test results were urinary protein excretion 3.5 g/day, serum creatinine 1.4 mg/dL, and serum albumin 3.1 g/dL. Type II (IgG-IgM- $\kappa$ ) MC was detected with a cryocrit of 24%. The serum levels of C4 were low (2.3 mg/dL; normal value, nv 20-50 mg/dL), and those of C3 were moderately reduced (46.8 mg/dL; nv 55-120 mg/dL). Alanine (ALT) and aspartate aminotransferases (AST) levels were in the normal range. The patient was negative for hepatitis B virus (HBV) markers, but positive for anti-HCV antibodies (detected using a second-generation enzyme immunoassay) and serum HCV RNA (assessed by means of a reverse transcriptase polymerase chain reaction [RT-PCR] assay). The genotype (characterised by means of PCR assay, using primers specific for the HCV core region) was 1b. A percutaneous renal biopsy showed type I MPGN with mild monocyte infiltration (Fig. 1A). The activity index based on light microscopy findings and the scoring system established for lupus nephropathy (35) was 5/24. Immunofluorescence staining showed granular IgM, IgG, and C3 deposits with a subendothelial pattern (Fig. 1B). Antiviral therapy was started with IFN- $\alpha$  3 million units (MU) thrice weekly and ribavirin 15 mg/kg/day. After 12 weeks of treatment, HCV RNA became undetectable, the edema and purpura improved, serum creatinine levels normalised (1.1 mg/dL), proteinuria decreased to 220 mg/day, cryocrit dropped to 2%, and serum C4 levels returned to normal. When the antiviral treatment was discontinued in week 24, HCV RNA and cryoglobulins were no longer found in the serum and all of the signs of renal disease had completely reversed. Except for a mild flu-like syndrome and a transient decrease in hemoglobin level (successfully managed by reducing the dose of ribavirin), the antiviral therapy was well tolerated. One year after the end of treatment, the patient was still in clinical and virologic remission.



**Figure 1.** HCV-associated cryoglobulinemic MPGN. (A) Increased mesangial hypercellularity with mild monocyte infiltration. Mesangial enlargement giving rise to lobular aspects. Irregular capillary wall thickening with double-contoured appearance (periodic acid-Schiff x 250). (B) Granular fluorescent IgG deposits along the capillary walls with a lobular distribution (x 250)

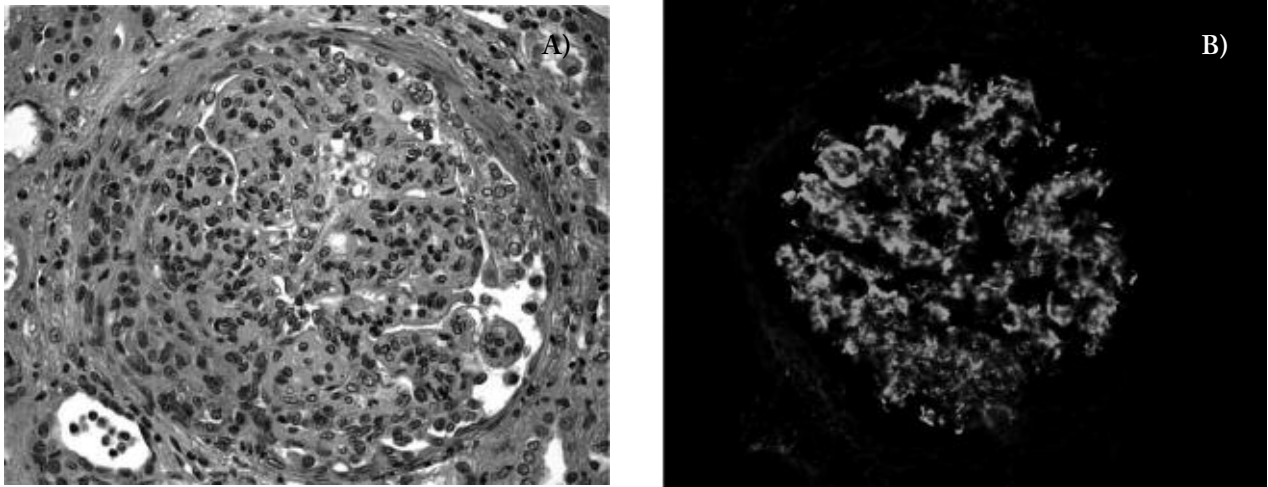
### Case 2

A 32-year-old man presented with edema of the legs, nephrotic-range proteinuria, elevated liver enzymes, and positive serum cryoglobulins. He had been in good health until one month before admission to our Department. Physical examination revealed leg edema, no hepatosplenomegaly, and a blood pressure of 130/80 mmHg. Laboratory tests showed slightly increased serum creatinine levels (1.5 mg/dL), proteinuria in the nephrotic range (8.5 g/day) with active urine sediment, reduced serum albumin (2.8 g/dL) and increased ALT levels (74 U/L; nv 0-35 U/L), positive serum RF (97 IU/mL; nv 0-15 IU/mL), and low serum C4 levels (4.75 mg/dL). Cryocrit was 31%, and cryoglobulin characterization revealed type II (IgG-IgM- $\kappa$ ) MC. The patient was negative for HBV infection markers, but positive for anti-HCV antibodies and HCV RNA (genotype 1b/1a). A percutaneous renal biopsy revealed type I MPGN with massive subendothelial deposits, numerous intracapillary eosinophilic thrombi, and some cellular crescents. Interstitial mononuclear cell infiltration was quite diffuse (Fig. 2A). The activity index based on light microscopy specimens was 15/24. Immunofluorescence microscopy revealed diffuse, granular IgM, IgG and C3 deposits in the capillary loops and mesangial areas, with intense massive staining of some intraluminal

deposits (Fig. 2B). After four months of treatment with IFN- $\alpha$  3 MU thrice weekly and ribavirin 15 mg/kg/day, HCV RNA was negative, cryocrit 3%, serum creatinine 1.1 mg/dL, and ALT levels had normalised. Proteinuria remained in the nephrotic range but had decreased to 4.1 g/day. Two months later, urinary protein excretion was 3.9-4.5 g/day and serum albumin 2.9 g/dl, serum creatinine remained stable, cryocrit was 1.5%, and serum HCV RNA was negative. The main adverse events related to the antiviral treatment were pruritus and a slight decrease in hemoglobin levels. After 12 months of antiviral therapy, his clinical and virologic condition remained essentially unchanged.

### Case 3

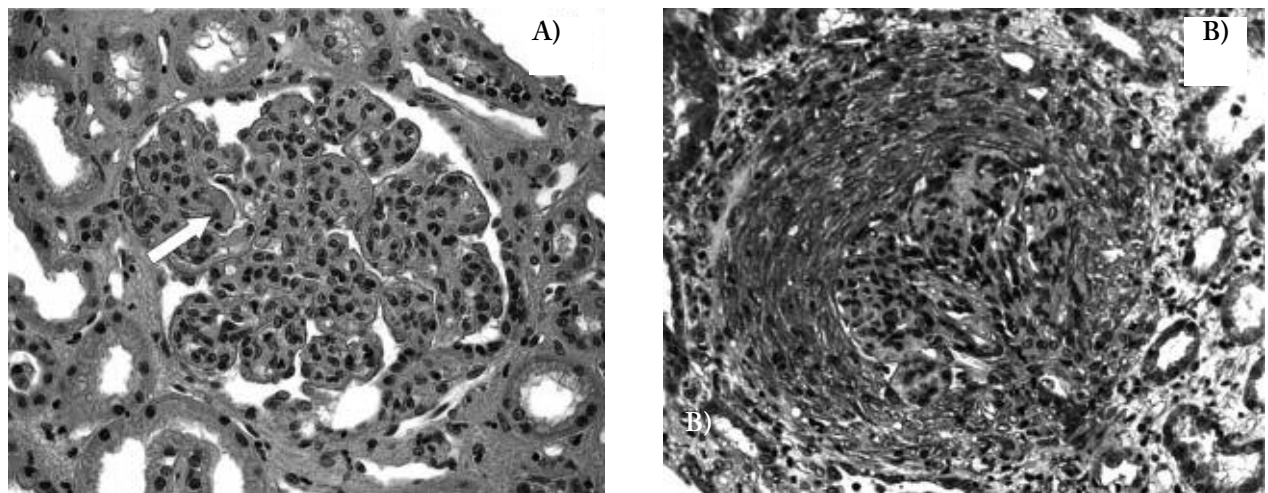
A 50-year-old man presented with a five-week history of arthralgia and ankle edema. The admission physical examination showed hypertension (180/100 mmHg), monolateral (right) pleural effusion, and edema of the legs. The laboratory findings were hemoglobin 11.8 g/dL, blood urea nitrogen (BUN) 45 mg/dL, creatinine 1.6 mg/dL with creatinine clearance 52 mL/min, total serum proteins 4.9 g/dL, albumin 2.5 g/dL, and cholesterol 402 mg/dL. ALT and AST levels were in the normal range. Urinalysis showed proteinuria (4+) with microscopic hematuria, leukocy-



**Figure 2.** HCV-associated cryoglobulinemic MPGN. (A) Broad proliferation of mesangial cells with monocyte infiltration. Huge subendothelial deposits and some intracapillary eosinophilic thrombi. The tuft is partly surrounded by an epithelial crescent (hematoxylin and eosin x 400). (B) Irregular C3 deposits in the capillary walls and the mesangial regions (x250)

turia and cellular casts. Urinary protein excretion was 10.5 g/24 h. The patient was negative for HBV surface antigen, and positive for HCV antibodies and HCV RNA; the genotype was 1 and the viral load  $7.6 \times 10^6$  copies/mL. The other laboratory results showed RF 871 IU/mL, C4 1.9 mg/dL, and cryocrit 20%. Immunofixation revealed type II (IgG-IgM- $\kappa$ ) MC. A liver biopsy showed mild chronic hepatitis (grade A1, stage F1 according to the METAVIR scoring system) (36). A percutaneous renal biopsy revealed exudative

MPGN with numerous intraluminal thrombi (Fig. 3A) and cellular crescents (Fig. 3B) in 7/23 glomeruli. The interstitium was edematous with diffuse leukocyte infiltration. One arteriole showed extensive fibrinoid necrosis of the wall and occlusion of the lumen. The activity index based on light microscopy specimens was 18/24. Immunofluorescence microscopy revealed granular capillary wall and mesangial deposits, and intraluminal masses of C3, IgM, and IgG. Electron microscopic examination confirmed the

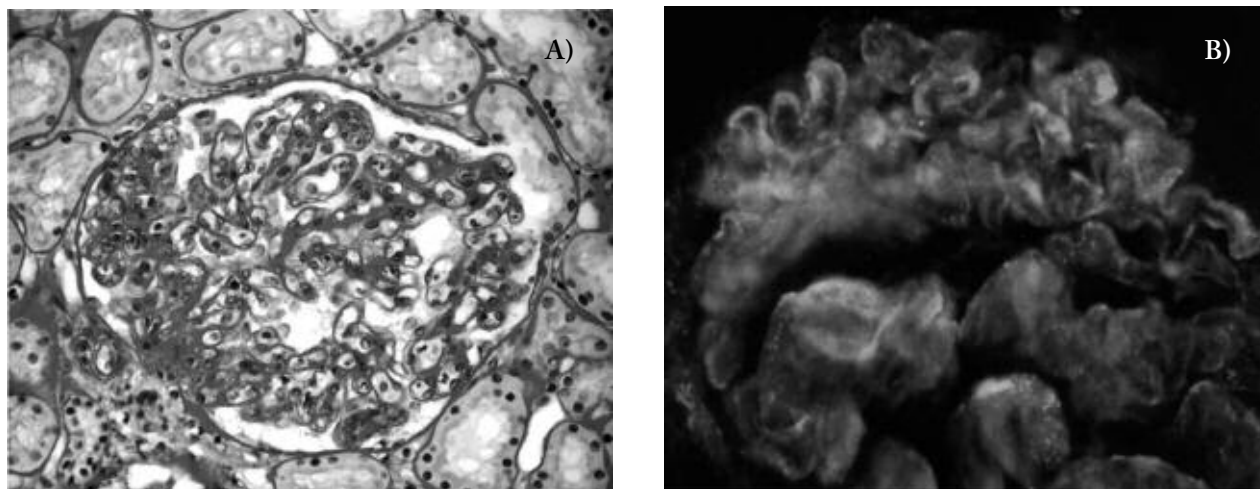


**Figure 3.** HCV-associated cryoglobulinemic MPGN. (A) Tuft mesangial proliferation with a lobular appearance and monocyte infiltration. Two intraluminal eosinophilic thrombi are visible (white arrow) (hematoxylin and eosin x 250). (B) Large circumferential cellular crescent with collapse of the tuft (trichrome x 250)

presence of large subendothelial immune complex deposits. Immunosuppressive treatment was started with corticosteroids (methylprednisolone pulses of 1.0 g/day for three days, followed by oral prednisone 1.0 mg/kg/day slowly tapered to a maintenance dose of 0.2 mg/kg/day) and oral cyclophosphamide (at a dose of 2 mg/kg/day). After three months, serum creatinine and creatinine clearance had normalised, proteinuria had decreased to 800 mg/24 h and cryocrit to 5%, and the systemic signs of the disease (edema, arthralgia) had disappeared. ALT and AST levels remained unchanged, whereas HCV RNA levels had increased ( $38,3 \times 10^6$  copies/mL). As the cryoglobulinemic MPGN was in clinical remission, cyclophosphamide and prednisone were discontinued, and antiviral treatment with once-weekly injections of peginterferon alfa-2a 100 µg combined with ribavirin 800 mg/day was started. Three months later, serum HCV RNA had disappeared, a result that was confirmed after six months, as well as at the end of antiviral therapy in week 48, and during the post-treatment follow-up. Proteinuria returned to the normal range (40 mg/24 h), cryoglobulins decreased to undetectable levels, and serum C4 levels normalised. RF activity decreased, but remained above normal. The antiviral therapy was well tolerated, but once-weekly subcutaneous treatment with erythropoietin 10,000 U.I. was required to maintain hemoglobin levels ( $\geq 12.0$  g/dL)

#### Case 4

A 69-year-old woman was admitted to our Department because of arthralgia, purpura, and edema of the legs, which had been recurrent during the previous five years. Upon admission, she had purpura and leg edema, and arterial hypertension (160/95 mmHg). The laboratory findings were hemoglobin 11.4 g/dL, BUN 22 mg/dL, creatinine 0.7 mg/dL, albumin 3.1 g/dL, and normal liver function. Urinalysis revealed heavy proteinuria (4+) with microscopic hematuria; 24-h urine collection showed 4,3 g of protein and creatinine clearance 76 mL/min. The patient was positive for HCV markers and HCV RNA; the genotype was 1b and the viral load  $6.4 \times 10^6$  copies/mL. Tests for HBV surface antigen were negative. Other laboratory investigations showed RF 125 IU/mL, C3 105 mg/dL, C4 5.4 mg/dL, and cryocrit 15%. Immunofixation revealed type II (IgG-IgM-κ) MC. A liver biopsy revealed mild chronic hepatitis (grade A1, stage F0), and a percutaneous renal biopsy showed features characteristic of a cryoglobulinemic type I MPGN, with uniform mesangial widening, an occasional increase in cellularity, and mild thickening of the capillary walls (Fig. 4A). There were no significant tubulo-interstitial changes or signs of vasculitis. The activity index based on light microscopy specimens was 6/24. Immunofluorescence microscopy showed granu-



**Figure 4.** HCV-associated cryoglobulinemic MPGN. (A) Mild mesangial widening with accentuated cell proliferation on the left side of the tuft. Capillary loops are irregularly thickened (periodic acid-Schiff x 250). (B) Fluorescent granular deposits of IgG along the capillary walls and in the mesangium showing a subendothelial pattern (x 400)

lar deposits of C3, IgG, and IgM, with a subendothelial pattern (Fig. 4B). Antiviral therapy was started with peginterferon alfa-2a 80 µg combined with daily ribavirin, the initial dose of which (15 mg/kg/day) was adjusted to maintain hemoglobin levels of 10–12 g/dL. No virological response was observed after 12, 24 or 48 weeks of treatment but, although HCV was not eradicated, the reduced viral load of  $0.9 \times 10^6$  copies/mL was associated with some favourable clinical and biochemical effects: cryocrit decreased to 10% and proteinuria to 0.4 g/24 h, the edema disappeared and the purpura improved. However, there was no appreciable change in the serum level of C4 or RF activity. The main side effects of antiviral treatment were hemolysis and a transient decrease in neutrophil and platelet counts. Six months after the discontinuation of therapy, the patient experienced a recurrence of purpura and arthralgia, with a concomitant increase in cryocrit (18%) and proteinuria (1.4 g/day). Interestingly, her circulating viral load and anti-HCV titres had reached pre-treatment levels.

## Discussion

All of our four patients with HCV-related CGN presented with the clinical and biochemical features of the nephrotic syndrome. Two patients showed serum creatinine levels of  $\geq 1.5$  mg/dL, and three were hypertensive. Chronic HCV infection was established in all the patients by means of the detection of serum anti-HCV antibodies and HCV RNA; liver involvement was mild and asymptomatic. All patients showed RF activity and had very low C4 levels. Percutaneous renal biopsies revealed type I MPGN in all four cases, and the presence of type-II (IgG-IgM- $\kappa$ ) MCs in their sera led to the diagnosis of cryoglobulinemic MPGN.

The most frequent renal involvement in patients with HCV infection is CGN, with type I MPGN being the predominant histologic pattern (18, 19, 21, 22). In cryoglobulinemic MPGN, light microscopy usually shows a diffuse endocapillary proliferative or mesangiocapillary lesion with crescents in a few glomeruli, thickened capillary basement membranes with a double-contoured or tram track appearance, and nu-

merous subendothelial deposits that sometimes also fill the capillary lumen (so-called “intraluminal thrombi”). Vasculitis with fibrinoid necrosis and/or proliferative arterial wall changes are seen in one-third of renal biopsy specimens (23). Immunofluorescence microscopy reveals granular capillary wall, mesangial and intraluminal deposits of C3, IgM, and IgG that are immunologically similar to the circulating cryoglobulins (37, 38). On electron microscopy the intraluminal and subendothelial deposits may show tubular and crystalline structures compatible with cryoglobulins (37, 39, 40).

The pathogenesis of CGN in HCV infection is unknown. The glomerular damage in HCV-related cryoglobulinemia may be due to the *in situ* or in-circulation binding of HCV antigens, polyclonal anti-HCV IgGs and non-specific IgGs to the IgM RF of MCs, with subsequent complement activation and cytokine production (18, 21). The demonstration of HCV antigens or RNA in renal tissue have frequently produced unreliable data, possibly because of low tissue HCV proteins levels, the poor affinity of monoclonal antisera, or antigen masking by circulating antibodies (19).

The treatment of HCV-related cryoglobulinemic MPGN can be focused either on suppression of viremia or on measures that interfere with the immune mechanisms responsible for glomerular damage. Antiviral therapy with IFN- $\alpha$  and ribavirin is currently considered the first-line treatment for HCV-related CGN, because it provides the best chance of viral clearance and subsequent disease improvement. There are no large-scale studies regarding the antiviral treatment of HCV-related CGN, but positive results have been reported in anecdotal observations as a consequence of the disappearance of HCV RNA from the serum, and a decrease in circulating cryoglobulin levels (25–31). However, HCV eradication is obtained in no more than 50% of the patients (41), and the clinical benefit of antiviral treatment is often transient or restricted to patients with low-grade kidney involvement (see case 1). In patients with severe renal disease, there is clinical evidence (see case 2) that, although it is capable of suppressing viremia and cryoglobulinemia, antiviral therapy is not fully effective in controlling the inflammatory and self-perpetuating immune-

mediated reaction that arises from cryoglobulin deposition in the vascular system and tissue. Furthermore, IFN- $\alpha$  therapy may be associated with worsening glomerulonephritis (32-34), and ribavirin may be contraindicated in the presence of renal failure (22, 34).

Deciding on the treatment is a complex issue that should take numerous variables into account, including the patient's age, general state of health, likelihood of response, and medical conditions that may decrease life expectancy or contraindicate the use of immunosuppressive or antiviral agents. Determining the activity and severity of the underlying renal disease is also of paramount importance. Clinical features such as nephritic syndrome with renal function impairment, and subnephrotic or nephrotic proteinuria with active urine sediment are valuable indicators of renal disease severity (18, 19). In addition, renal biopsy can be used not only to establish the diagnosis, but also to make therapeutic decisions since it may contribute to identifying the patients who would most benefit from antiviral or immunosuppressive therapy. Specific histological findings suggesting a renal flare include prominent glomerular monocyte infiltration, intraluminal thrombi, large crescents, and vasculitis with fibrinoid necrosis (18-20, 23). On the basis of these clinical and histological features, patients can be classified as having mild-moderate or severe/active renal disease (42).

The primary goal in patients with mild-to-moderate kidney involvement (e.g. glomerulonephritis with stable renal function, inactive urine sediment, and mild or moderate renal biopsy histological lesions) is to eradicate HCV, and so combined therapy with pegylated IFN- $\alpha$  and ribavirin should be considered as first-line treatment. The duration of antiviral therapy is similar to that in patients with chronic HCV infection (12 months for patients with genotype 1, less for patients with genotype 2 or 3) (41, 43). The complete remission of MPGN is subordinate to a sustained virological response but, as observed in our case 4, some patients may benefit from combined therapy even in the absence of HCV clearance (28, 31, 44). This favourable, albeit transient, response of MC-related symptoms is attributable to the immunomodulatory/anti-inflammatory action of ribavirin and a decrease in HCV viral load.

In patients with severe/active renal disease (e.g. nephritic syndrome with increasing creatinine values, nephrotic syndrome with active urine sediment, and severe renal biopsy histological lesions), immunosuppressive therapy should take priority over antiviral treatment (18, 29, 42, 45). A short-term (8-12 weeks) course of corticosteroids (500-1000 mg of methylprednisolone daily for three days, followed by oral prednisone 1.0 mg/kg/day for 1 month with subsequent gradual tapering) and cyclophosphamide (administered orally at 2 mg/kg/day) should be started to improve the acute manifestations of renal disease and to decrease the production of cryoglobulins (17-19, 42, 45). In the most severe cases, plasmapheresis (exchanges of 3 L of plasma 3-4 times/week for 2-3 weeks) can be used to remove cryoglobulins, inflammation mediators and toxins. There is concern that immunosuppressive therapy may increase viral replication and viremia, but no consistent evidence of acute liver damage has been reported during short-term treatment with corticosteroids and cytotoxic agents (18, 19, 46). When clinical remission has been achieved (indicated by stable or falling creatinine levels, the absence of urinary cell casts and a reduction in proteinuria), the immunosuppressive drugs should be stopped and replaced by antiviral treatment to eradicate HCV, the causative agent of CGN. In our case 3, this strategy led to the complete remission of MPGN and long-lasting suppression of viremia and cryoglobulinemia. Although the sequential administration of immunosuppressive and antiviral agents is a reasonable therapeutic approach to HCV infected patients with severe/active CGN, further studies are needed to confirm its efficacy and safety.

With regard to patients in whom antiviral therapy is ineffective, counterindicated or not tolerated, it has recently been proposed that rituximab, a human/mouse chimeric monoclonal antibody against B-cell surface antigen CD20, may be an alternative to standard immunosuppressive treatment (47, 48), which is difficult to manage and implies a high risk of serious side effects after long-term use. Monoclonal anti-CD20 antibody targets and depletes B-cells clones that sustain the production of pathogenetic cryoglobulins. In symptomatic patients with HCV-associated CGN, it has been found that rituximab reduces pro-

teinuria, RF activity, Ig concentration and cryocrit levels, despite increased viremia (approximately twice that measured at baseline) (47, 49). The long-term efficacy and safety of rituximab now needs to be compared with those of conventional treatment in randomised, controlled studies of patients with type II MC syndrome and, particularly, CGN.

## Acknowledgments

We are indebted to Dr Luisa Carnevali for the histological specimens, and Dr. Pietro Schianchi and Dr. Danio Somenzi for their computer support.

## References

1. Agnello V, De Rosa F. Extrahepatic disease manifestations of HCV infection: some current issues. *J Hepatol* 2004; 40: 341-52.
2. Brouet JC, Clauvel JP, Danon F, Lein M, Seligmann M. Biologic and clinical significance of cryoglobulins: A report of 86 cases. *Am J Med* 1974; 57: 775-88.
3. Musset L, Diemert MC, Taibi F, et al. Characterization of cryoglobulins by immunoblotting. *Clin Chem* 1992; 38: 798-802.
4. Pascual M, Perrin L, Giostra E, Schifferli J. Hepatitis C virus in patients with cryoglobulinemia type II. *J Infect Dis* 1990; 162: 569-70.
5. Ferri C, Greco F, Longobardo G, et al. Association between hepatitis C virus and mixed cryoglobulinaemia. *Clin Exp Rheumatol* 1991; 9: 621-4.
6. Agnello V, Chung RT, Kaplan LM. A role for hepatitis C virus infection in type II cryoglobulinemia. *N Engl J Med* 1992; 327: 1490-5.
7. Choo Q, Kuo G, Weiner AJ, Overby LR, Bradley DW, Houghton M. Isolation of cDNA clone derived from a blood-borne non-A, non-B viral hepatitis genome. *Science* 1989; 244: 359-62.
8. Trejo O, Ramos-Casals M, Garcia-Carrasco M, et al. Cryoglobulinemia. Study of etiologic factors and clinical and immunologic features in 443 patients from a single center. *Medicine* 2001; 80: 252-62.
9. Cacoub P, Renou C, Rosenthal E, et al. Extrahepatic manifestations associated with hepatitis C virus infection: a prospective multicenter study of 321 patients. *Medicine (Baltimore)* 2000; 79: 47-56.
10. Monti G, Galli M, Invernizzi F, et al. Cryoglobulinemias: A multi-centre study of the early clinical and laboratory manifestations of primary and secondary disease. *Q J Med* 1995; 88: 115-26.
11. De Vita S, De Re V, Gasparotto D, et al. Oligoclonal non-neoplastic B cell expansion is the key feature of type II mixed cryoglobulinemia: Clinical and molecular findings do not support a bone marrow pathological diagnosis of indolent B cell lymphoma. *Arthritis Rheum* 2000; 43: 94-102.
12. Ferri C, Greco F, Longobardo G, et al. Association between hepatitis C virus and mixed cryoglobulinaemia. *Clin Exp Rheumatol* 1991; 9: 621-4.
13. Monteverde A, Ballarè M, Pileri S. Hepatic lymphoid aggregates in chronic hepatitis C and mixed cryoglobulinemia. *Springer Semin Immunopathol* 1997; 19: 99-110.
14. Pileri P, Uematsu Y, Campagnoli S, et al. Binding of hepatitis C virus to CD81. *Science* 1998; 282: 938-41.
15. Meltzer M, Franklin EC, Elias K, McCluskey RT, Cooper N. Cryoglobulinemia. A clinical and laboratory study. II. Cryoglobulins with rheumatoid factor activity. *Am J Med* 1966; 40: 837-56.
16. Gorevic PD, Kassab HJ, Levo Y, et al. Mixed cryoglobulinemia: clinical aspects and long-term follow-up of 40 patients. *Am J Med* 1980; 69: 287-308.
17. Lamprecht P, Gause A, Gross WL. Cryoglobulinemic vasculitis. *Arthritis Rheum* 1999; 42: 2507-16.
18. D'Amico G. Renal involvement in hepatitis C infection: Cryoglobulinemic glomerulonephritis induced by hepatitis C virus. *Kidney Int* 1998; 54: 650-71.
19. Johnson RJ, Gretch DR, Yamabe H, et al. Membranoproliferative glomerulonephritis associated with hepatitis C virus infection. *N Engl J Med* 1993; 328: 465-70.
20. Beddhu S, Bastacky S, Johnson JP. The clinical and morphologic spectrum of renal cryoglobulinemia. *Medicine* 2002; 81: 398-409.
21. Fornasieri A, D'Amico G. Type II mixed cryoglobulinaemia, hepatitis C virus infection, and glomerulonephritis. *Nephrol Dial Transplant* 1996; 11 (Suppl 4): 25-30.
22. Meyers CM, Seeff LB, Stehman-Breen CO, Hoofnagle JH. Hepatitis C and renal disease: an update. *Am J Kidney Dis* 2003; 42: 631-57.
23. Tarantino A, Campise M, Banfi G, et al. Long-term predictors of survival in essential mixed cryoglobulinemic glomerulonephritis. *Kidney Int* 1995; 47: 618-23.
24. Mazzaro C, Panarello G, Tesio F, et al. Hepatitis C virus risk: a hepatitis C virus related syndrome. *J Int Med* 2000; 247: 535-45.
25. Johnson RJ, Gretch DR, Couser WG, et al. Hepatitis C virus-associated glomerulonephritis. Effect of alpha-interferon therapy. *Kidney Int* 1994; 46: 1700-4.
26. Yamabe H, Johnson RJ, Gretch DR, et al. Membranoproliferative glomerulonephritis associated with hepatitis C virus infection responsive to interferon-alpha. *Am J Kidney Dis* 1995; 25: 67-9.
27. Sarac E, Bastacky S, Johnson JP. Response to high dose interferon- $\alpha$  after failure of standard therapy in MPGN associated with hepatitis C virus infection. *Am J Kidney Dis* 1997; 30: 113-5.
28. Misiani R, Bellavita P, Baio P, et al. Successful treatment of HCV-associated cryoglobulinemic glomerulonephritis with a combination of interferon- $\alpha$  and ribavirin. *Nephrol Dial Transplant* 1999; 14: 1558-60.
29. Garini G, Allegri L, Carnevali L, Catellani W, Manganel-

- li P, Buzio C. Interferon-alpha in combination with ribavirin as initial treatment for hepatitis C virus-associated cryoglobulinemic membranoproliferative glomerulonephritis. *Am J Kidney Dis* 2001; 38: E35.
30. Loustaud-Ratti V, Liozon E, Karaaslan H, et al. Interferon alpha and ribavirin for membranoproliferative glomerulonephritis and hepatitis C infection. *Am J Med* 2002; 113: 516-9.
31. Rossi P, Bertani T, Baio P, et al. Hepatitis C virus-related cryoglobulinemic glomerulonephritis: long-term remission after antiviral therapy. *Kidney Int* 2003; 63: 2236-41.
32. Boonyapisit K, Katiirji B. Severe exacerbation of hepatitis C-associated vasculitic neuropathy following treatment with interferon alpha: a case report and literature review. *Muscle Nerve* 2002; 6: 909-13.
33. Gordon AC, Edgar JD, Finch RG. Acute exacerbation of vasculitis during interferon-alpha therapy for hepatitis C-associated cryoglobulinaemia. *J Infect* 1998; 36: 229-30.
34. Otha S, Yokoyama H, Wada T, et al. Exacerbation of glomerulonephritis in subjects with chronic hepatitis C virus infection after interferon therapy. *Am J Kidney Dis* 1999; 33: 1040-8.
35. Austin HA, Muenz LR, Joyce KM, et al. Prognostic factors in lupus nephritis. Contribution of renal histological data. *Am J Med* 1983; 75: 382-91.
36. Bedossa P, Poynard T. An algorithm for the grading of activity in chronic hepatitis C. *Hepatology* 1996; 24: 289-93.
37. Cordonnier D, Martin H, Gros Lambert P, Micouin C, Chenais F, Stoebner P. Mixed IgG-IgM cryoglobulinaemia with glomerulonephritis. Immunohistochemical fluorescent and ultrastructural study of kidney and in vivo cryoprecipitate. *Am J Med* 1975; 59: 867-72.
38. Sinico AR, Winearls CG, Sabadini E, Fornasieri A, Castiglioni A, D'Amico G. Identification of glomerular immune deposits in cryoglobulinaemia glomerulonephritis. *Kidney Int* 1988; 34: 1-8.
39. Feiner H, Gallo G. Ultrastructure in glomerulonephritis associated with cryoglobulinemia. *Am J Pathol* 1977; 88: 145-62.
40. Stoebner P, Renversez JC, Groude J, Vialtel P, Cordonnier D. Ultrastructural study of human IgG and IgG-IgM crystalcryoglobulins. *Am J Clin Pathol* 1979; 71: 404-10.
41. Fried MW, Shiffman ML, Reddy KR, et al. Peginterferon alfa-2a plus ribavirin for chronic hepatitis C virus infection. *N Engl J Med* 2002; 347: 975-82.
42. Vassilopoulos D, Calabrese LH. Hepatitis C virus infection and vasculitis. Implications of antiviral and immunosuppressive therapies. *Arthritis Rheum* 2002; 46: 585-97.
43. McHutchison JG, Hoofnagle JH. Therapy of chronic hepatitis C. In Liang TJ, Hoofnagle JH (eds): *Hepatitis C*. San Diego: Academic Press, 2000: 203-39.
44. Lopes E, Lopes LV, Silva AE. Mixed cryoglobulinemia and membranoproliferative glomerulonephritis associated with hepatitis C virus infection. *Ann Intern Med* 1996; 125: 781-2.
45. Campise M, Tarantino A. Glomerulonephritis in mixed cryoglobulinemia: what treatment? *Nephrol Dial Transplant* 1999; 14: 281-3.
46. Fong TL, Valinluck B, Govindarajan S, Charboneau F, Adkins RH, Redeker AG. Short-term prednisone therapy affects aminotransferase activity and hepatitis C virus RNA levels in chronic hepatitis C. *Gastroenterology* 1994; 107: 196-9.
47. Sansonno D, De Re V, Lauletta G, Tucci FA, Boiocchi M, Dammacco F. Treatment of mixed cryoglobulinemia resistant to interferon-alpha with an anti-CD 20 monoclonal antibody. *Blood* 2003; 101: 3818-26.
48. Zaja F, De Vita S, Mazzaro C, et al. Efficacy and safety of rituximab in type II mixed cryoglobulinemia. *Blood* 2003; 101: 3827-34.
49. Roccatello D, Baldovino S, Rossi D, et al. Long-term effects of anti-CD20 monoclonal antibody treatment of cryoglobulinemic glomerulonephritis. *Nephrol Dial Transplant* 2004; 19: 3054-61.

Accepted: 2<sup>nd</sup> July 2006

Correspondence: Giovanni Garini, M.D.

Department of Internal Medicine,

Nephrology and Health Sciences

University Hospital,

Via A. Gramsci 14,

43100 Parma, Italy

Tel. 0521 702347

Fax 0521 292627

E-mail: giovanni.garini@unipr.it, www.actabiomedica.it