

Pancreas procurement technique. Lessons learned from an initial experience

Raffaele Dalla Valle, Enzo Capocasale, Maria Patrizia Mazzoni, Nicola Busi, Mario Sianesi

Department of Surgical Science, University of Parma, Parma, Italy

Abstract. *Background and aim of the study:* Multiorgan procurement requires good anatomical knowledge and perfect synchronization between surgeons to ensure adequate dissection of visceral vessels. The aim of this article is to assess a technique for pancreas procurement in a multiorgan donor. *Methods:* starting our program of pancreas transplantation we adopted a technique for “in situ” simultaneous recovery of pancreas, liver and small bowel when indicated. We performed 3/4 of the dissection with an intact donor circulation of the organs so that the cold ischemia time was kept to a minimum. The technique was used in 18 multiorgan cadaveric donors during a period of 74 months. Seventeen out of 18 pancreatic grafts were transplanted simultaneously with a kidney. The small intestine was transplanted in one case and the liver in 18 cases. *Results:* None of the transplanted pancreases sustained serious ischemic or vascular injuries. One pancreatic graft was discarded due to iatrogenic vascular injury during the procurement. Vascular surgical complications included 1 portal thrombosis, 1 iliac graft thrombosis and 1 iliac graft pseudoaneurysm. Pancreas allograft removal was necessary in 4 patients. All the retrieved liver and the small intestine were successfully transplanted elsewhere. *Conclusions:* All except one of the pancreatic grafts retrieved with this technique were of excellent quality. A perfect coordination between the different surgical equities is mandatory in order to limit the risk of vascular injury, particularly in the presence of anatomical variations. (www.actabiomedica.it)

Key words: Pancreas transplantation, multivisceral procurement

Introduction

Improved results of pancreas transplantation have led to an increasing demand of this complex procedure also in Europe, even if the annual number is still limited for several reasons. One of the critical points is represented by the procurement technique. The pancreas donor is normally a young cadaver almost always suitable for multiorgan procurement. Consequently the removal of the pancreas with the liver and or the intestine poses a technical problem in maintaining an axial blood supply to each organ, without damaging the individual need of the recipients. This complex technique has been originally described by Starzl in 1984 (1), but some variants have subsequently been reported (2-6) Herein we describe how we are met

this technical challenge in a series of 18 cadaveric donors whose organs were used to perform 17 pancreas transplants, 18 liver transplants and 1 intestinal transplant.

Methods

The 18 multiorgan procurements were all performed in our Region of Emilia Romagna between June 1998 and April 2005, according to widely recognized criteria of multiple organ procurement, ABO compatibility, appropriate size-match, minimal or no intravenous doses of vasopressors, normal levels of blood sugars and serum lipases and normal results of liver function tests. (7) Human leukocyte antigen matching

with the recipients was random. All but one of the procurements were performed by surgical teams of our Region. Celsior solution was used for both in situ flushing and cold storage in 15 cases and University of Wisconsin solution was used in 3 cases.

Preparation of the donor included selective gut decontamination (amphotericin B, tobramycin and ceftriazone) administered through a nasogastric tube at the time of procurement. In addition, standard intravenous antibiotic prophylaxis was performed with a third-generation cephalosporine. All procedures began with a thorough celiotomy in order to assess the presence of vascular anomalies and the absence of parenchymal injury. The abdominal aorta was then distally encircled for the insertion of an infusion cannula in order to start with the cold perfusion in the presence of hemodynamic instability. We performed 3/4 of the dissection with an intact donor circulation of the organs. The left coronary and triangular ligament were divided and the abdominal aorta was encircled above the celiac axis for later cross-clamping. Hepatic arterial supply was first checked in order to identify all the anomalous hepatic arteries that must be preserved. The cecum, ascending colon and hepatic flexure were completely mobilized to expose the vena cava with the origin of the renal veins. An extended Kocher manoeuvre allowed the exposure of the abdominal aorta, the right side of the mesenteric vein and isolation of the origin of the superior mesenteric artery (SMA). The middle colic vein and artery were divided and ligated. The common bile duct was distally ligated and transected. The gallbladder was incised and the bile was washed out. After incision of the gastrohepatic ligament and division of the right gastric and gastroduodenal arteries, the common hepatic artery was dissected until the celiac trunk (TC), allowing the complete exposure of the portal vein above the pancreas. We recommend securing all the lymphovascular tissue on the upper edge of the pancreas to prevent post-reperfusion hemorrhage. The origin of the splenic artery (SA) was then carefully isolated and encircled (Figure 1). The left gastric artery was preserved in the presence of an accessory left hepatic artery. A complete dissection of the colo-epiploic ligament and the short gastric vessels was performed. The distal pylorus was then encircled and transected with a GIA stapling de-

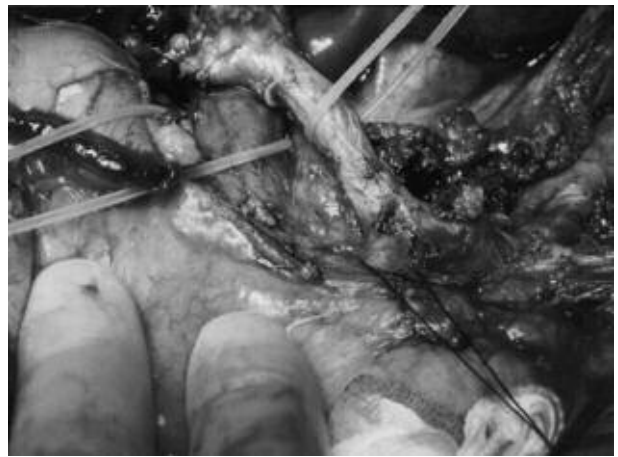


Figure 1. Celiac trunk, common hepatic artery, the origin of the splenic artery and the portal vein are dissected and encircled

vice (Ethicon), allowing an optimal exposure of the pancreas. The proximal jejunum was transected after obtaining further mobilization by dividing the ligament of Treitz and the inferior mesenteric vein. The highest jejunal vascular arcades were divided in order to expose the left side of the mesenteric pedicle. The SMA and superior mesenteric vein (SMV) were then isolated right to the inferior edge of the pancreas, sparing the upper pancreaticoduodenal vessels (Figure 2). This is a critical point of the dissection when the small intestine is also provided. Preserving the inferior pancreaticoduodenal artery (IPA) intact is mandatory sin-

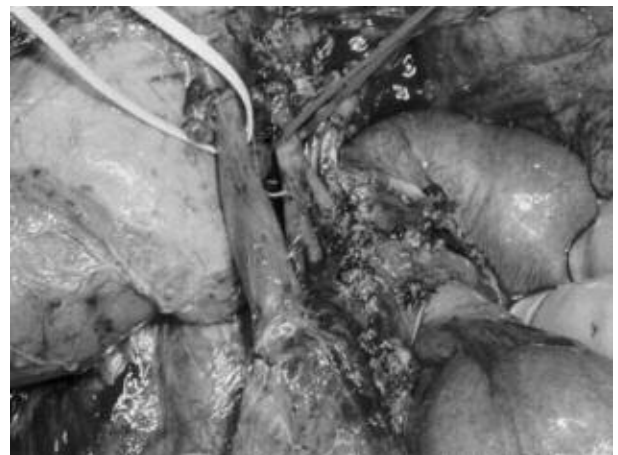


Figure 2. Complete dissection of the mesenteric pedicle. The mesenteric vein and artery are isolated up to the origin of the IPA and encircled

ce is the only way to perfuse the head and part of the uncinate process of the pancreas. An injury to the IPA renders the graft useless. In order to minimize the risk of damaging this vessel we stopped the dissection of the SMA just proximal to the origin of the first jejunal trunk. During the dissection, pancreas manipulation must be limited and performed carefully. After completion of the preliminary dissections, the donor was fully heparinized and the distal aortic cannula was placed. Celsior or Wisconsin solution was infused after the previously encircled supraceliac aorta was cross-clamped. Infusion volume via the aortic cannula was approximately 5000 to 6000 mL. Portal venous infusion was not contemplated in our protocol. In order to avoid overperfusion of the pancreas we carefully clamped the origin of the splenic artery after 2000 mL of infusion and partially divide the portal vein (PV). The organs remained in situ until the cold infusion was complete. When indicated, the small intestinal graft was removed first with the ascending colon; the SMA and SMV were divided leaving a cuff of about 0.5cm including the inferior pancreaticoduodenal artery and vein. With this technique the pancreas is separated in situ from the liver and not on the back-table as originally described by Starzl.

The body and tail of the pancreas with the spleen were divided from the adrenal gland and the retroperitoneum and the left border of the aorta was freed of lymphatic and neuroganglionic tissues.

The section of the PV was completed approximately 1 to 2 cm above the pancreas in order to leave both the liver and the pancreas with adequate lengths of PV. After transection of the vena cava and the aorta over the origin of the renal vein and arteries, the origin of the SMA was isolated and transected leaving a short proximal segment with the pancreas. If a replaced hepatic artery is found to arise from the SMA, the anomalous vessel almost always originates proximally to the IPA. In this circumstance, the SMA was transected between the origins of the two branches, leaving the proximal SMA in continuity with the anomalous hepatic artery and the distal SMA in continuity with the IPA. The pancreas graft was then removed and the aorta with the TC remained with the liver that is removed after section of the vena cava.

During this dissection stretch injuries to the vessels should be avoided to prevent intimal tears, which may result in arterial thrombosis. It is imperative at the end of the procurement procedures to obtain a large supply of high-quality arterial and venous grafts. (8-10) These are frequently needed for the transplantation of one, two, or even all three organs. The most commonly used vascular grafts are the iliac and carotid arteries and the iliac or jugular veins. A bifurcated iliac arterial graft is normally required for the pancreas. After removing the pancreas we reperfuse the graft on the bench work.

Results

All but one of the pancreases recovered were successfully transplanted simultaneously with a kidney to recipients with type I diabetes and renal failure. One pancreas graft was not transplanted due to a iatrogenic lesion of the IPA from a replaced right hepatic artery during the procurement. The cause of death was trauma for 14 donors (77%) and spontaneous cerebral hemorrhage for 4 (23%). Average donor age (12 males and 6 females) was 27 years (range 12-40). The mean time of in vivo dissection was 106 min. (range 85-130). Average cold ischemic time was 12 hours and 10 minutes, whereas average warm ischemic time was 50 minutes. No patient mortality was observed. No primary or delayed graft function was observed both for pancreas and kidney. One acute rejection episode and 5 surgical (29.4%) and 2 medical complications (11.7%) occurred. Surgical complications included 1 portal thrombosis, 1 arterial thrombosis, 1 iliac graft pseudoaneurysm and a duodenal stump leakage. Pancreas allograft removal was necessary in 4 patients (23.5%). In 6 cases a re-laparotomy was necessary (35.2%). Medical complication comprised 1 acute pancreatitis and 1 inferior limb deep venous thrombosis. All patients became insulin-free within 24-48 hours. All the other recipients are insulin-free at a median follow-up of 12 months. No hemorrhagic complication was observed at reperfusion.

All the retrieved liver grafts and the intestinal graft were successfully transplanted elsewhere in our region.

Discussion

Despite the well documented effects of pancreas transplantation on quality of life in diabetic patients and its life-saving value, the rate of this type of transplant is still low in Italy, probably due to the complexity of pancreas procurement with a high risk of vascular damage and /or necessity of difficult vascular reconstruction. In the history of visceral transplantation whole pancreas procurement was initially considered as incompatible with procurement of the liver and recently of the intestine. Since pancreas transplantation was considered an option for diabetic patients, pancreas procurement was initially sacrificed in order to guarantee an optimal liver graft. Progress in surgical dissection and vascular reconstruction techniques in recent years led to the development of advanced techniques for the retrieval of liver, pancreas and intestine from the same donor without risk of vascular damage. Perfect knowledge of vascular anatomy of all three organs and its variations is mandatory to perform a safe multiorgan procurement. Two different surgical techniques are presently employed: rapid cooling of all the donor organs, en bloc procurement and organ separation on the backtable, or in vivo dissection, cold perfusion and in situ separation of the donor organs.(3) The en bloc procurement technique is described as rapid and particularly useful in the presence of hemodynamic instability of the donor. The application of this technique is recommended when the same team performs liver, pancreas and kidney transplants and the same surgeon performs all the organ separations on the backtable just before the transplantations. Procurement of all abdominal organs by the same team facilitates coordination of the surgeons and standardization of the technique, limiting the risks of injury from manipulation and inadvertent rewarming. In vivo dissection needs a perfect knowledge of the anatomy and is criticized by some surgeons for the longer time of dissection before the cold perfusion (3, 8). Since the techniques of organ procurement are different in our Region, at the beginning of our program of pancreas transplantation we planned a common strategy and decided to adopt the in vivo dissection technique in order to optimize the multivisceral procurement, assuring a minimal cold ischemia ti-

me and an excellent organ quality at transplantation. In our experience the mean time of in vivo dissection has been of 106 min. In vivo dissection is influenced more by the experience and ability of the operating surgeon, while the back table dissection is facilitated by the easy exposure of the vascular structure, even if the dissection is performed by a posterior approach that makes more complex the learning phase and the anatomical landmarks.

Cold ischemia time is reduced in our opinion by the in vivo dissection technique. Three-fourths of the organ donor dissections were performed before the cold perfusion. Therefore the pancreas dissection is particularly accurate limiting the need of a long backtable surgery. In all our cases, capsular bleeding and pancreatic edema at the reperfusion of the graft were minimal.

A critical point of the pancreas procurement procedure is the preservation of the IPA when a replaced/accessory right hepatic artery is found (9, 10). The vitality of the pancreatic graft is strictly dependent on the retention of this vessel. In the presence of a right hepatic artery arising from the SMA it was initially recommended to abandon the pancreas procurement in order to preserve the hepatic vessel. Today a careful retrograde dissection of the vessel allows the preservation of the integrity of the arterial distribution to the liver and the pancreas. Once recognized the IPA, the SMA is transected just caudal to the origin of the replaced hepatic artery. In our opinion, the in vivo technique allows for a more accurate dissection of an anomalous right hepatic artery just to its level of origin from the SMA allowing for an exact decision on the feasibility of the procurement. We believe that the major limit of this technique is the need for a perfect coordination between the équipes involved in the procurement. Changing the sequence of time of the procedure may lead to iatrogenic vascular lesions which occurred in one of our cases where the transection of the IPA forced us to abandon the pancreatic graft.

The other crucial point of pancreas procurement is the dissection of the SA. We limited its manipulation to its origin from the TC in order to preserve an intact vessel for the revascularization of the pancreatic allograft. Before starting the cold perfusion we also as-

sured a partial section of the PV in order to favour the washout of the pancreas and limit its overperfusion, which is considered a risk factor for post-operative pancreatitis.

The intestinal, pancreatic, and liver allografts retrieved with the described technique and subsequently transplanted were of excellent quality. None of the recipients lost their grafts because of intraabdominal infection, preservation injury, or a technically flawed donor procedure. Post-operative vascular complications (23%) in our initial experience are similar to that reported in large series and are not strictly related to the procurement procedure.

References

1. Starzl TE, Hakala TR, Shaw BW Jr, et al. A flexible procedure for multiple cadaveric organ procurement. *Surg Gynecol Obstet* 1984; 158: 223-30.
2. Starzl TE, Miller C, Bronznick B, Makowka L. An improved technique for multiple organ harvesting. *Surg Gynecol Obstet* 1987; 165: 343-8.
3. Boggi U, Vistoli F, Del Chiaro M, et al. A simplified technique for the en bloc procurement of abdominal organs that is suitable for pancreas and small-bowel transplantation. *Surgery* 2004; 135: 629-41
4. Yersiz H, Renz JF, Histake GM, et al. Multivisceral and isolated intestinal procurement techniques. *Liver transplantation* 2003; 9: 881-6.
5. Imagawa Dk, Olthoff KM, Yersiz H, et al. Rapid en bloc technique for pancreas-liver procurement. *Transplantation* 1996; 61: 1605-9.
6. Pinna AD, Dodson FS, Smith CV, et al. Rapid en bloc technique for liver and pancreas procurement. *Transplant Proc* 1997; 29: 647-8.
7. Starzl TE, Todo S, Tzakis A, et al. The many faces of multivisceral transplantation. *Surg Gynecol Obstet* 1991; 172: 335-44.
8. Dodson F, Pinna A, Jabbour N, et al. Advantages of the rapid en bloc technique for pancreas/liver recovery. *Transplant Proc* 1995; 27: 3050.
9. Molmenti EP, Klein AS, Henry ML. Procurement of liver and pancreas allografts in Donors with replaced/accessory right hepatic arteries. *Transplantation* 2004; 78: 770-1
10. Abu-Elmagd K, Fung JJ, Bueno J, et al. Logistics and technique for procurement of intestinal, pancreatic and hepatic grafts from the same donor. *Ann Surg* 2000; 5: 680-7.

Accepted: September 2006

Correspondence: Raffaele Dalla Valle, MD

Department of Surgical Science

Via Gramsci, 14

43100 Parma, Italy

Tel. 0521.702180

Fax 0521.992501

E-mail: r.dalval@unipr.it, www.actabiomedica.it