

Bone necrosis of the jaws associated with bisphosphonate treatment: a report of twenty-nine cases

Elisabetta Merigo¹, Maddalena Manfredi¹, Marco Meleti¹, Rebecca Guidotti¹, Alessandro Ripasarti¹, Elisa Zanzucchi¹, Pietro D'Aleo¹, Domenico Corradi², Luigi Corcione², Enrico Sesenna³, Silvano Ferrari³, Tito Poli³, Mauro Bonanini¹, Paolo Vescovi¹

¹Unit of Oral Pathology and Medicine, Section of Odontostomatology, Department of ENT/Dental/Ophthalmological and Cervico-Facial Sciences, University of Parma, Parma, Italy; ²Pathology Section, Department of Pathology and Laboratory Medicine, University of Parma, Parma, Italy; ³Section of Maxillo-Facial Surgery, Department of ENT/Dental/Ophthalmological and Cervico-Facial Sciences, University of Parma, Parma, Italy

Abstract. Bone necrosis of the jaws is often related to head and neck radiotherapy, to surgical procedures at maxillary or mandibular level but also to various local and systemic factors such as haematological diseases, haemoglobinopathies and systemic lupus eritematosus; its pathogenesis maybe associated with defects of vascularization. Bisphosphonate are synthetic analogues of pyrophosphate used for the treatment of hypercalcemia in patients with malignancies and bone metastasis and for the treatment of many other disorders such as metabolic bone diseases, Paget's disease, and osteoporosis; their pharmacological activity is related to the inhibition of the osteoclastic function which leads to resorption and reduction of bone vascularization. Since the end of 2003 Bisphosphonate-associated Osteonecrosis (BON) has become an increasing problem and the test of that is the increase of the relative published case report and case series. Here we report 29 cases of bone necrosis of the jaws in patients treated with pamidronate (Aredia), zoledronate (Zometa) and alendronate: 15 underwent surgical procedures and 14 occurred spontaneously. Among these patients (21 females, 8 males; mean age between 45 and 83 years); 14 were treated for bone metastasis, 12 for multiple myeloma and 3 for osteoporosis. Bone necrosis involved only maxilla in 7 patients, only mandible in 20 patients and both in 2 patients. Six patients had multiple osteonecrotic lesions, 3 contemporary lesions and 3 non contemporary. In these patients we performed 3 kinds of therapy, associated or not: medical therapy (with antibiotic drugs, antimycotics and antiseptic mouthwashes), surgical therapy with curettage or sequestrectomy and Nd:YAG laser biostimulation. (www.actabiomedica.it)

Key words: Bone necrosis, jaw, bisphosphonates, pamidronate, zoledronate, alendronate, bone metastasis, multiple myeloma

Introduction

Osteonecrosis is the death of a bone or a part of a bone that results as a natural consequence of a wide variety of systemic and local factors compromising the blood flow within the bone; these include haemoglobinopathies, anticardiolipin antibodies, and defects of the thrombotic and fibrinolytic systems, fat emboli, al-

coholism, systemic lupus erythematosus and corticosteroid administration (1-3).

From the clinical point of view, bone necrosis of the jaws usually appears as an exposure of avascular bone in the mandible, in the maxilla, or in both (2). The exposed necrotic bone is infected and the area is usually painful; patients may complain of difficulty in eating and speaking, pain, bleeding and, when the ne-

crisis is extensive and near to the mandibular branch of the trigeminal nerve, paresthesia of the lower lip (2). The main cause of bone necrosis is a defect in vascularization (2-3). In the oral cavity, bone necrosis in immunodepressed patients is probably related to the presence of unhealthy teeth, which increase the risk of infection; in fact, bone necrosis is usually related to tooth extraction. In some cases, bone necrosis is associated with corticosteroid treatment or with radiotherapy.

In this work, we report twenty-nine cases of jaw osteonecrosis in patients treated with bisphosphonates for bone metastasis, multiple myeloma or osteoporosis.

The twenty-nine reported cases were referred to the Unit of Oral Pathology and Medicine, Section of Odontostomatology, Department of ENT/Dental/Ophthalmological and Cervico-Facial Sciences, University of Parma, Parma, Italy, by five different Oncology Departments of Parma, Piacenza, Cremona and Reggio Emilia, between January 2004 and April 2006.

Case report

The ages of the twenty-nine cases (8 males and 21 females) ranged between 45 and 83 years; twelve of these patients had a diagnosis of multiple myeloma, fourteen of bone metastasis and three of osteoporosis.

The patients with malignancies showed bone metastasis within a period that went from 4 to 17 years after the cancer diagnosis.

None of these patients had a history of endocrine disorders, particularly parathyroid disorders which are frequently associated with bone disease. Different kinds of chemotherapeutic drugs were administered before treatment with bisphosphonates (Tab. 1).

Eleven patients started therapy with pamidronate that was subsequently replaced with zoledronate; fifteen patients were directly treated with zoledronate after diagnosis and three patients with alendronate. Pamidronate (90 mg) was administered every 4 weeks (intravenously over a 2- to 4-hour period), zoledronate (4 mg) was administered every 4 weeks (infusion over a period of 15 minutes) and alendronate (70 mg)

was administered orally every week (Tab. 2).

None of the patients were treated with radiotherapy and corticosteroids. Fourteen patients had previous tooth extractions at the same site of bone necrosis and the time between the extraction and the beginning of symptoms varied between one month and one year; one patient had to remove the implants where the osteonecrosis occurred.

At the first oral examination all patients showed an ulcerative lesion with bone exposure (1-5 cm) (Fig. 1-4). They complained of pain, bleeding and paresthesia of the lower lip within a period between 1 month and 5 years from the beginning of bisphosphonate therapy (Tab. 2).

Histopathological examination revealed a necrotic osteitis associated with a mixed infiltrate of lymphocytes and granulocytes. No histological features of bone metastasis or multiple myeloma within the lesions could be observed.

In these patients, in relation to clinical characteristics, we applied medical therapy associated or not with surgical therapy (sequestrectomy and bone debridement), with or without Nd:YAG laser biostimulation. Medical treatment with antibiotics [amoxicillin 2 gr/die per os or ceftazidim 1 gr/die i.m. and metronidazole 500 mg/die per os] and antimycotics [fluconazole 100mg/die per os] was started and continued for 15 days. Mouth-washes with chlorhexidine and hydrogen peroxide were also prescribed.

With the applied therapies, we had partial successes, in particular with medical treatment, with or without surgery, associated with Nd:YAG laser biostimulation.

Discussion

In this work, we describe 29 cases of jaw osteonecrosis following treatment with bisphosphonate, particularly pamidronate and zoledronate, widely used for their efficacy in the treatment of hypercalcemia in patients with malignancies or bone cancer metastasis.

Bisphosphonates are stable analogues of pyrophosphate with a P-C-P structure and two side chains attached to the carbon atom: the first chain controls the ability of binding to crystals in the bone,

Table 1. Characteristics of patients: medical history, symptomatology and therapy

Patient	Sex	Age	First diagnosis	Time of first diagnosis	Diagnosis of metastasis	Metastasis type	Chemotherapy
C.M.	F	56	Breast cancer	1993	1997	Bone metastasis	Ciclofosamid+Metotrexate+5-Fluorouracil (5-FU); Epiadriamicina+Docetaxel; Vinorelbine+5-FU
B.L.	F	64	Pleura mesothelioma	1997	2002	Mesothelioma and bone metastasis	Gemcitabine+ Vinorelbine
R.C.	F	59	Breast cancer	2000	2001	Liver and metastasis	Ciclofosamid+Metotrexate+5-FU; Epiadriamicina+ Docetaxel; Vinorelbine+5-FU
S.E.	F	71	Multiple myeloma	2002	-	-	-
V.L.	F	83	Breast cancer	2001	2002	Bone metastasis	Docetaxel
G.V.	M	79	Multiple myeloma	1997	-	-	-
S.C.	F	78	Breast cancer	1985	2002	Bone metastasis	Capecitabin+Nitomicin; Fluorouracil+Nitomicin; Paclitaxel
N.M.	F	62	Multiple myeloma	1977	-	-	-
F.L.	F	83	Breast cancer	1985	2002	Bone metastasis	Docetaxel (2002-2004)
T.S.	M	64	Multiple myeloma	1998	-	-	-
S.A.	M	70	Multiple myeloma	1998	2003	-	Ciclofosamid
M.A.	M	67	Multiple myeloma	2002	-	-	-
B.J.	F	79	Multiple myeloma	2000	-	-	-
B.F.	F	74	Multiple myeloma	2000	-	-	-
C.R.	F	74	Breast cancer	2000	2004	Bone metastasis	Doxorubicina
F.V.	M	77	Multiple mieloma	2003	-	-	-
F.P.	F	70	Osteoporosis	2002	-	-	-
G.L.	F	58	Breast cancer	2002	2004	Bone metastasis	Ciclofosamid+Metotrexate+5-Fluorouracil- Tamoxifene
G.E.	F	74	Breast and kidney cancer	1986	1999	Bone metastasis	Letrozole
M.A.	F	61	Osteoporosis	2003	-	-	-
M.R.	M	72	Multiple myeloma	1992	-	-	-
P.A.	F	45	Breast cancer	1995	2003	Bone metastasis	-
P.M.	F	70	Breast cancer	2003	2005	Bone metastasis	Ciclofosamid+Epirubicina+ Fluorouracil
R.I.	F	67	Breast cancer	1996	2004	Bone metastasis	-
S.I.	F	78	Osteoporosis	2001	-	-	-
S.A.	M	63	Prostate cancer	1997	2004	Bone metastasis	-
T.F.	M	66	Multiple myeloma	1998	-	-	-
T.R.	F	71	Breast cancer	2004	2005	Bone metastasis	-
T.M.	F	76	Multiple myeloma	2005	-	-	Bortezomib

Table 2. Bisphosphonates therapy and clinical aspects of bone necrosis

	Therapy	Start therapy	Replacement therapy	New therapy	Symptoms	Beginning of symptoms	Site of bone necrosis	Dental extraction	Time of dental extraction	End of therapy
C.M.	Pamidronate	2002 (Nov)	2003 (Set)	Zoledronate	Pain-Bleeding-Paresthesia lower lip-Ear pain	2003 (Aug)	Left mandible	-	-	2003 (Sep)
B.L.	Pamidronate	2001 (Feb)	2002 (Apr)	Zoledronate	Pain	2003 (Jan)	Right mandible	-	2003 (Jan)	2004 (Feb)
R.C.	Zoledronate	2003 (Feb)	-	-	Pain	2003 (Sep)	Left maxilla and mandible	-	-	2004 (Jan)
S.E.	Zoledronate	2002	-	-	Pain-Paresthesia lower lip	2003 (Apr)	Mandible (medial)	3.5	2002	2004 (Mar)
V.L.	Pamidronate	2002	2002	Zoledronate	Pain	2003 (Aug)	Left mandible	-	2003 (Aug)	2003 (Dec)
G.V.	Pamidronate	1997	2003 (Feb)	Zoledronate	Pain-Paresthesia lower lip	2004 (Dec)	Right mandible	-	-	2004 (Dec)
S.C.	Pamidronate	2002 (Apr)	2002 (Nov)	Zoledronate	Pain	2005 (Jan)	Right mandible	4.4-4.5-4.6	2004 (Oct)	2004 (Apr)
N.M.	Pamidronate	2002	2003	Zoledronate	Pain	2005 (Mar)	Left maxilla	2.6	2005 (Feb)	2005 (Apr)
F.L.	Zoledronate	2004 (Jan)	-	-	Pain	2005	Right mandible	4.5	2005 (Feb)	2005 (Jan)
T.S.	Pamidronate	1999 (Feb)	2001 (May)	Zoledronate	Pain- Paresthesia lower lip	2004 (Oct)	Left mandible	Implants left mandible	2004 (Nov)	2003 (Jul)
S.A.	Zoledronate	2003	-	-	Pain	2004 (Jun)	Right mandible	4.5	2005 (Jun)	2005 (Apr)
M.A.	Zoledronate	2002	-	-	Pain- Bleeding-Paresthesia lower lip	2005 (Feb)	Left mandible	3.5	2005 (Mar)	2005 (Mar)
B.J.	Pamidronate	2002 (Dec)	2003 (Nov)	Zoledronate	Pain	2005 (Feb)	Left mandible	-	-	2005 (Jul)
B.F.	Zoledronate	2003 (Oct)	-	-	Pain	2005 (Sep)	Left-Right maxilla	-	-	-
C.R.	Pamidronate	2004 (Jul)	2004 (Oct)	Zoledronate	Pain	2005 (Dec)	Left mandible	-	-	-
F.V.	Zoledronate	2003 (Dec)	-	-	Pain	2005 (Aug)	Right-Left maxilla	1.6	2005 (Aug)	2004 (Mar)

(continued)

Table 2. Bisphosphonates therapy and clinical aspects of bone necrosis

	Therapy	Start therapy	Replacement therapy	New therapy	Symptoms	Beginning of symptoms	Site of bone necrosis	Dental extraction	Time of dental extraction	End of therapy
F.P.	Alendronate	2002	-	-	Pain	2005 (Jul)	Left mandible	3.5	2005 (Jul)	2005
G.L.	Zoledronate	2004 (Aug)	-	-	Pain	2005 (Apr)	Right-Left maxilla	1.5	2005 (Feb)	-
G.E.	Pamidronate	1999	2002 (Nov)	Zoledronate	Pain	2005 (May)	Right mandible	4.6	2005 (Jul)	2004 (Dec)
M.A.	Alendronate	2003 (Oct)	-	-	Pain	2006 (Jan)	Right maxilla	1.7	2005 (Dec)	2006 (Mar)
M.R.	Zoledronate	2005 (Feb)	-	-	Pain	2006 (Mar)	Right mandible	-	-	-
P.A.	Pamidronate	2003 (Dec)	2004 (Dec)	Zoledronate	Pain	2006 (Feb)	Left maxilla	-	-	-
P.M.	Zoledronate	2005 (May)	-	-	Pain	2006 (Jan)	Right mandible	-	-	-
R.I.	Zoledronate	2004 (Jan)	-	-	Pain	2005 (Jul)	Right mandible	-	-	-
S.I.	Alendronate	2001 (Jan)	-	-	Pain	2005 (Jul)	Right mandible	4.6	2005 (Sep)	2005 (Sep)
S.A.	Zoledronate	2004 (Sep)	-	-	Pain	2005 (Jun)	Right mandible	4.7	2005 (Jul)	-
T.F.	Zoledronate	2004 (Oct)	-	-	Pain- Paresthesia lower lip	2005 (Aug)	Right mandible	4.6	2005 (May)	-
T.R.	Zoledronate	2005 (Jun)	-	-	Pain	2005 (Jan)	Medial maxilla	-	-	-
T.M.	Zoledronate	2005 (Oct)	-	-	Pain-Paresthesia lower lip- Abscess	2006 (Jan)	Right-Left maxilla-Left mandible	3.5-3.6	2005 (Oct)	2006 (Mar)

while the second chain determines the efficacy of the bisphosphonates (4, 5). Pamidronate and zoledronate are nitrogen-containing bisphosphonates which inhibit the enzymes of the mevalonate pathway (6). Bisphosphonates are absorbed, stored and excreted unchanged from the body; their plasma half-life is short (between 20 minutes and 2-3 hours), while their bone half-life is very long (from months to years). About 50% of the absorbed drug is located in the bone, with

a high affinity for bone areas where bone resorption and formation is taking place (7). The action of bisphosphonates is related to their effect on osteoclasts and to the resorption of bone, limiting the tumour growth. Bisphosphonates also cause the apoptosis of tumor cells through their action on the mevalonate pathway (4, 8, 9). Moreover, nitrogen bisphosphonates (pamidronate and zoledronate) have shown the ability of inhibiting the adhesion of tumor cells to and over

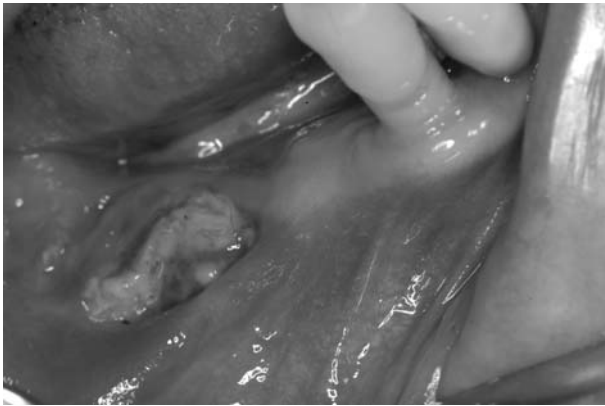

Figure 1. Bone necrosis of the left mandible in a female patient (S.C.) with bone metastasis under treatment with pamidronate and zoledronate.

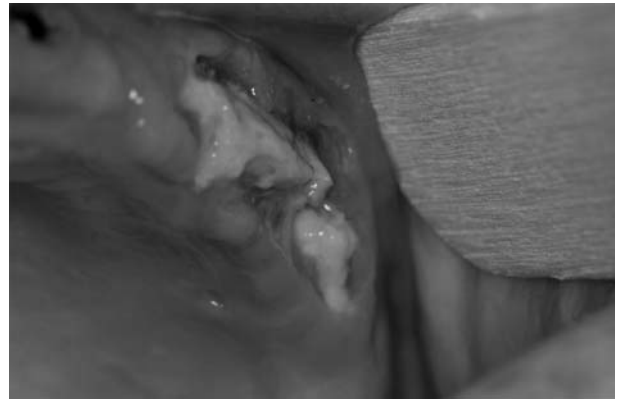

Figure 4. Bone necrosis of the left maxilla in a female patient (R.C.) with liver and bone metastasis under treatment with zoledronate.

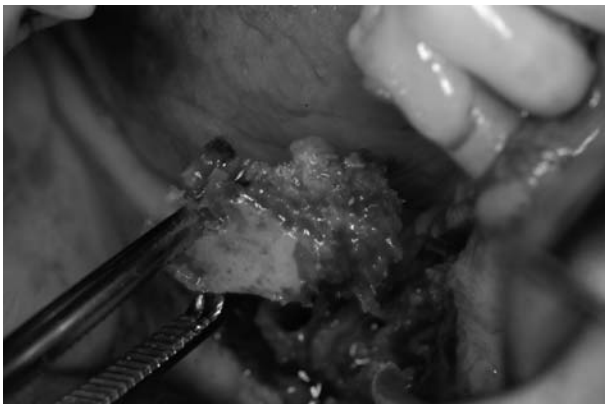


Figure 2. Treatment of the patient S.C.: surgical curettage with removal of the bone sequestrum (sequestrectomy).

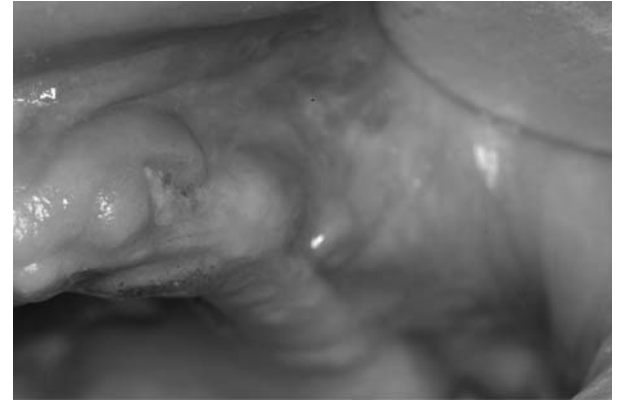

Figure 5. Post-surgical view of the left maxilla (R.C.) 3 months after the treatment.

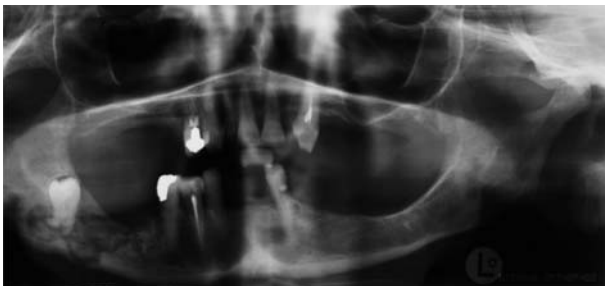

Figure 3. Radiographic view of the osteonecrosis of the right mandible in a female patient (B.L.) with bone metastasis under treatment with pamidronate and zoledronate.

bone matrix *in vitro*. Bisphosphonates also inhibit various metalloproteinases (MMPs) (such as MMP2-9-12) involved in cancer growth and metastasis *in vitro* (10-11). The reduction of osteoclastic activity reduces bone resorption and therefore bisphosphonates are used in multiple myeloma. Bisphosphonates are also used for reducing hypercalcemia in some malignancies and osteolysis in bone metastasis (12-19). It has recently been demonstrated that bisphosphonates inhibit endothelial cell functions and that pamidronate inhibits not only bone resorption and bone loss, but also bone blood flow (20-21).

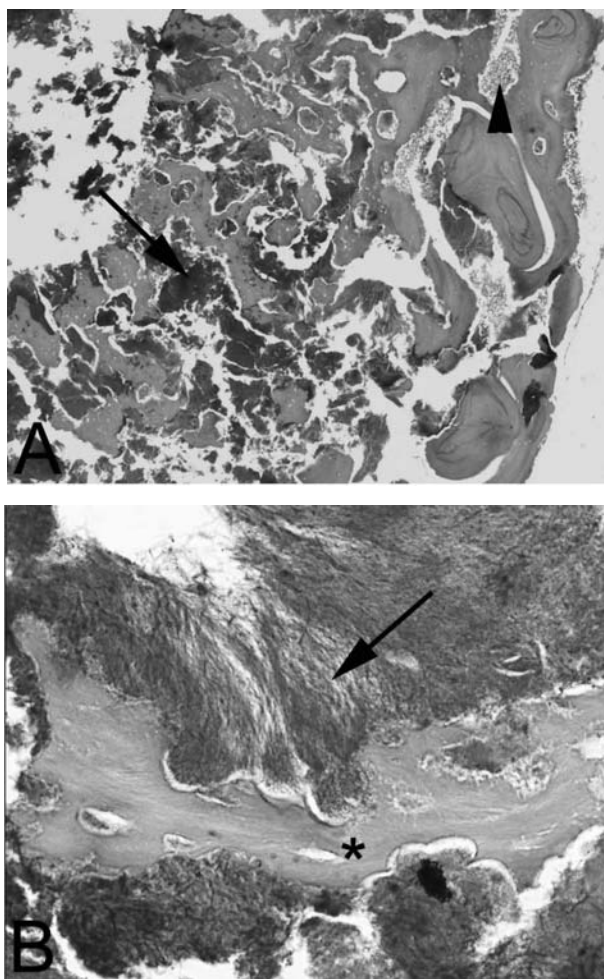


Figure 6. (A and B): Low power appearance of a sequestered necrotic bone showing clusters of microorganisms (arrow) diffusely filling the medullary space as well as a granulocytic infiltrate (arrowhead). Haematoxylin and Eosin, original magnification x4; (B): Detail of A. A fragment of necrotic cancellous bone (asterisk) is surrounded by colonies of *Actinomyces* appearing as filamentous microorganisms (arrow). PAS, original magnification x20.

Nitrogen-containing bisphosphonates are more active than other non-nitrogen-containing bisphosphonates such as etidronate, residronate and tiludronate and do not generally cause bone necrosis. These oral bisphosphonates are potent osteoclast inhibitors and are not as effective in malignant osteolytic disease (22); furthermore, pamidronate and bisphosphonates are not metabolized.

Recently, several authors reported bone necrosis of the jaws associated with bisphosphonate use (22-

29), both in patients that were treated with radiotherapy or chemotherapy and in those that were not.

Our patients did not present any risk factors for osteitis such as radiotherapy, treatment with corticosteroids or systemic disease, but in fourteen of them jaw osteonecrosis developed after dental extractions (30-33). At first, according to the oncologist, the patients interrupted the bisphosphonates therapy before or immediately after the first oral evaluation and before surgical treatment: actually, because of the long half-life of bisphosphonates and the lack of evidence on discontinuation of bisphosphonates therapy once osteonecrosis develops or before invasive dental procedures, the patients continue the bisphosphonates therapy. Moreover, there is no published evidence on the efficacy of aggressive surgical treatment or hyperbaric oxygen therapy in bisphosphonates-associated osteonecrosis management (34).

Based on the probable correlation between jaw osteonecrosis and bisphosphonates, before and during bisphosphonates therapy, a careful evaluation of the patients and a strict collaboration between dentists and oncologists is essential for the prevention of this side effect. Before the beginning of bisphosphonates treatment it is necessary to evaluate the patient's oral health in terms of good oral hygiene and plaque control, and appropriate restorative, endodontic, periodontal and surgical treatments in order to prevent any possible cause of infection which may reach the bone and avoid invasive oral interventions such as dental extractions or periodontal surgical treatments in the near and intermediate future.

All patients already receiving bisphosphonates should be referred to a dentist or oral maxillofacial surgeon for a careful examination. Surgery within the jaws, such as removal of third molar teeth or dental implants, is strongly discouraged at this time (29).

References

1. Gruppo R, Glueck CJ, McMahon RE, et al. The pathophysiology of alveolar osteonecrosis of the jaw: anticardiolipin antibodies, thrombophilia, and hypofibrinolysis. *J Lab Clin Med* 1996; 127 (5): 481-8.
2. Bouquot JE, McMahon RE. Neuropathic pain in maxillofacial osteonecrosis. *J Oral Maxillofac Surg* 2000; 58: 1003-20.

3. Assouline-Dayana Y, Chang C, Greenspan A, Shoenfeld Y, Gershwin ME. Pathogenesis and natural history of osteonecrosis. *Semin Arthritis Rheum* 2002; 32 (2): 94-124.
4. Ross JR, Saunders Y, Edmonds PM, et al. A systematic review of the role of bisphosphonates in metastatic disease. *Health Technology Assessment* 2004; 8 (4).
5. Rogers MJ, Benford HL, Coxon FP, Luckman SP, Monkkonen J, Frith JC. Cellular and molecular mechanism of action of bisphosphonates. *Cancer* 2000; 88: 2961-78.
6. Li EC, Pavis LE. Zoledronic acid: a new parenteral bisphosphonate. *Clin Ther* 2003; 25(11): 2669-708.
7. Lin JH. Bisphosphonates: a review of their pharmacokinetic properties. *Bone* 1996; 18(2): 75-85.
8. Body JJ. Rationale for the use of bisphosphonates in osteoblastic and osteolytic bone lesions. *The Breast* 2003, Supplement 2: S37-S44.
9. Body J. Rationale for the use of bisphosphonates in osteoblastic and osteolytic bone lesions. *Breast* 2003; 12 Suppl 2: S37-44.
10. John A, Tuszynski G. The role of matrix metalloproteinases in tumor angiogenesis and tumor metastasis. *Pathol Oncol Res* 2001; 7(1): 14-23.
11. Brown JE, Neville-Webbe H, Coleman RE. The role of bisphosphonates in breast and prostate cancers. *Endocr Relat Cancer* 2004; 11 (2): 207-24.
12. Djulbegovic B, Wheatley K, Ross J, et al. Bisphosphonates in multiple myeloma (Cochrane Review). In: *The Cochrane Library*, Issue 1, 2004. Chichester, UK: John Wiley & Sons, Ltd.
13. Pavlakis N, Stockler M. Bisphosphonates for breast cancer (Cochrane Review). In: *The Cochrane Library*, Issue 1, 2004. Chichester, UK: John Wiley & Sons, Ltd.
14. Wong R, Wiffen PJ. Bisphosphonates for the relief of pain secondary to bone metastases (Cochrane Review). In: *The Cochrane Library*, Issue 1, 2004. Chichester, UK: John Wiley & Sons, Ltd.
15. Rodan GA. Bone mass homeostasis and bisphosphonate action. *Bone* 1997; 20 (1): 1-4.
16. Roodman GD. Mechanism of bone metastasis. *N Engl J Med* 2004; 350: 1655-64.
17. Berenson JR, Hillner BE, Kyle RA, et al. American Society of Clinical Oncology clinical practice guidelines: the role of bisphosphonates in multiple myeloma. *J Clin Oncol* 2002; 20 (17): 3719-36.
18. Cameron D. Role of bisphosphonates therapy in breast cancer and other advanced malignancies. *Breast* 2003; 12 Suppl 2: S20-1.
19. Cameron D. Proven efficacy of zoledronic acid in the treatment of bone metastases in patients with breast cancer and other malignancies. *The Breast* 2003; Supplement 2, S22-9.
20. Kapitola J, Zac J. Effect of pamidronate on bone blood flow in oophorectomized rats. *Physiol Res* 1998; 47: 237-40.
21. Fournier P, Boissier S, Filleur S, et al. Bisphosphonates inhibit angiogenesis in vitro and testosterone-stimulated vascular regrowth in the ventral prostate in castrated rats. *Cancer Research* 2002; 62: 6538-44.
22. Ruggiero SR, Mehrotra B, Rosemberg TJ, Engroff SL. Osteonecrosis of the jaws associated with the use of bisphosphonates: a review of 63 cases. *J Oral Maxillofac Surg* 2004; 62: 527-34.
23. Bagan JV, Murillo J, Jimenez Y, et al. Avascular jaw osteonecrosis in association with cancer chemotherapy: series of 10 cases. *J Oral Pathol Med* 2005; 34 (2): 120-3.
24. Migliorati CA. Bisphosphonates-associated oral osteonecrosis. *Oral Surg Oral Med Oral Pathol Oral Radiol Endod* 2005; 99 (2): 135.
25. Migliorati CA. Bisphosphonates and oral cavity avascular bone necrosis. *Journal Clin Oncol* 2003; 21(22): 4253-8.
26. Wang J, Goodger NM, Pogrel MA. Osteonecrosis of the jaws associated with cancer chemotherapy. *J Oral Maxillofac Surg* 2003; 61: 1104-7.
27. Marx RE. Pamidronate (Aredia) and zoledronate (Zometa) induced avascular necrosis of the jaws: a growing epidemic. *J Oral Maxillofac Surg* 2003; 61: 1115-8.
28. Migliorati CA, Schubert MM, Peterson DE, et al. Bisphosphonate-associated osteonecrosis of mandibular and maxillary bone. *Cancer* 2005.
29. Marx RE, Sawatari Y, Fortin M, et al. Bisphosphonate-induced exposed bone (osteonecrosis/osteopetrosis) of the jaws: risk factors, recognition, prevention, and treatment. *J Oral Maxillofac Surg* 2005; 63(11): 1567-75.
30. Merigo E, Manfredi M, Meleti M, et al. Jaw bone necrosis without previous dental extractions associated with the use of bisphosphonates (pamidronate and zoledronate): a four case report. *J Oral Pathol Med* 2005; 34: 613-7.
31. Merigo E, Manfredi M, Meleti M et al. Osteonecrosi dei mascellari associata a bifosfonati. Casi clinici. *Dental Cadmos* 2006; 3: 71-8.
32. Vescovi P, Merigo E, Manfredi M, et al. Gestione dell'osteonecrosi dei mascellari da bifosfonati: uso della biostimolazione laser. *Dental Cadmos* 2006; 7: 1-9 (in press).
33. Vescovi P, Merigo E, Manfredi M. Bisphosphonate-associated osteonecrosis (BON) of the jaws: a possible treatment? *J Oral Maxill Surg* (in press).
34. Woo SB, Hellstein JW and Kalmar J. Systematic review: bisphosphonates and osteonecrosis of the jaws. *Ann Intern Med* 2006; 144: 753-61.

Accepted: 5th July 2006

Correspondence: Elisabetta Merigo

Sezione di Odontostomatologia

Dipartimento di Scienze Otorino-Odonto-Oftalmologiche

e Cervico-Facciali

Via Gramsci, 14

43100 Parma, Italy

Tel: +39-0521-702034

Fax: +39-0521-292955.

E-mail: elisabetta.merigo@unipr.it, www.actabiomedica.it

During November 2005 has been created in Parma a Study Group for Bisphosphonate-Associated Osteo Necrosis (BON), which included all medical specialities related to this condition.

Oral Medicine

Prof. Paolo Vescovi - Dott.ssa Maddalena Manfredi - Dott.ssa Elisabetta Merigo - Dott. Marco Meleti -
Dott.ssa Rebecca Guidotti - Dott. Alessandro Ripasarti - Dott.ssa Elisa Zanzucchi

Maxillo-Facial Surgery

Prof. Enrico Sesenna - Prof. Silvano Ferrari - Dott. Tito Poli - Dott. Andrea Ferri -
Dott. Alfredo Balestrieri - Dott.ssa Alessandra Multinu

Oncology

Prof. Andrea Ardizzoni - Dott.ssa Beatrice Di Blasio - Dott.ssa Mariangela Bella - Dott. Guido Ceci-
Dott.ssa Maria Michiara - Dott.ssa Stefania Salvagni

Internal Medicine

Prof. Roberto Delsignore - Prof.ssa Maria Cristina Baroni - Dott. Giovanni Passeri

Hematology

Prof. Vittorio Rizzoli - Dott. Nicola Giuliani

Oral Pathology

Dott. Luigi Corcione - Dott. Domenico Corradi

Pharmacology

Prof. Fabio Caliumi - Dott.ssa Alessandra Zanardi

Nephrology

Prof. Carlo Buzio - Dott. Paolo Greco

Radiology

Dott. Gian Franco Chiari

Oncology (Piacenza)

Dott.ssa R. Bertè - Dott.ssa E. Trabacchi

ENT (Piacenza)

Dott. Aldo Oppici - Dott. Luigi Cella

NOVARTIS

Paolo Filippi - Carlo Pagani