

Operating risks evaluation in posterior transolecranon surgical approach: the traffic lights model¹

Andrea Emilio Salvi

Orthopaedic and Traumatologic Department, 2^a Orthopaedic and Traumatologic Division, University of Brescia and Spedali Civili of Brescia, Brescia, Italy

The posterior transolecranon surgical approach of the elbow is often carried out in the treatment of the distal humerus fracture, especially intercondylar T and Y fractures (1). It consists of an olecranon osteotomy in order to visualize the articular face including a part of the diaphysis. The median exposed articular surface for this approach is very large (2). Notwithstanding the advantages of the wide area exposed, there are always two hazards to take into consideration: the presence of the ulnar nerve and the olecranon osteotomy-osteosynthesis performance. Because of the possibility of making mistakes during this approach, in my opinion it possible to apply a decreasing degree of risk, passing from medial to lateral compartment, that can be compared to a traffic lights put transverse the elbow.

According to this point of view, the maximum risk (red light) is located in the medial side of the elbow where the ulnar nerve can be damaged (Fig. 1), the intermediate risk (yellow light) is located in the olecranon: an incorrect osteotomy or an unsuitable osteosynthesis can fail the operation, and the complete lack of risk (green light) is located in the lateral side of the elbow.

Therefore, the surgical approach is always performed starting from the maximum risk identified by the red light, isolating the ulnar nerve, coming along the olecranon with its osteotomy and finishing the surgical process on the lateral side (Figs. 2, 3).

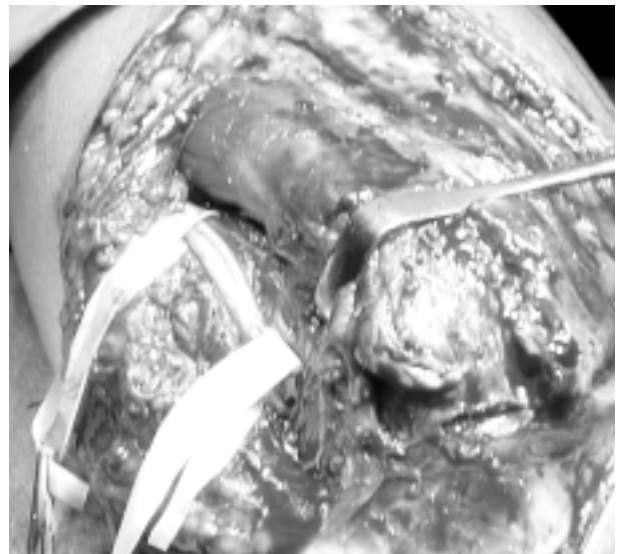


Figure 1. The ulnar nerve must be carefully identified and isolated, shifted with ribbons fasten to Kocher pincers.

The ulnar nerve palsy is the most dangerous eventuality during the transolecranon approach (3), and therefore this nerve must be carefully isolated and mobilized (4). It represents the “red light”: it passes along the epitrochlear gutter where it bends before the forearm. In order not to be compressed, it is useful to start its exposition with Metzemaum scissors proximally rather than distally. Once its full visualization is obtained, it is advisable to shift it on lateral side using

¹ Presented as Poster at the 7th National Congress of the S.I.C.S. e G. (Italian Society of Shoulder and Elbow surgery) - Modena, Italy, June 2004 and presented as E-poster at the 5th Biennial Congress of the I.S.A.K.O.S. (International Society of Arthroscopy, Knee Surgery and Orthopaedic Sports Medicine) - Hollywood, Florida, U.S.A., April 2005

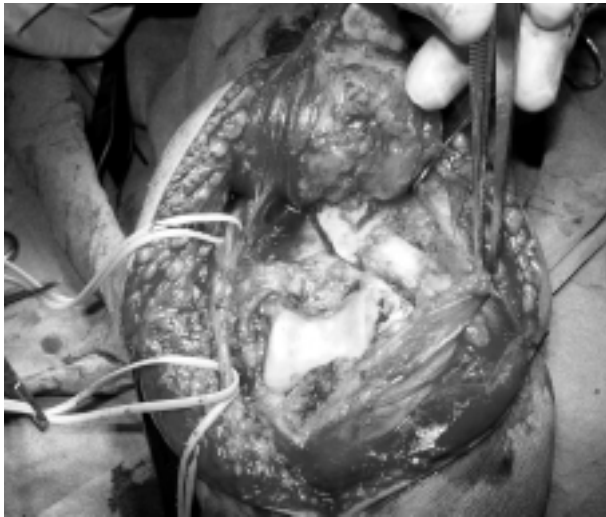


Figure 2. Once performed, the transolecranon approach permits to obtain a great exposure of the articular surface. Ulnar nerve is visible and the osteotomized olecranon is tipped up.

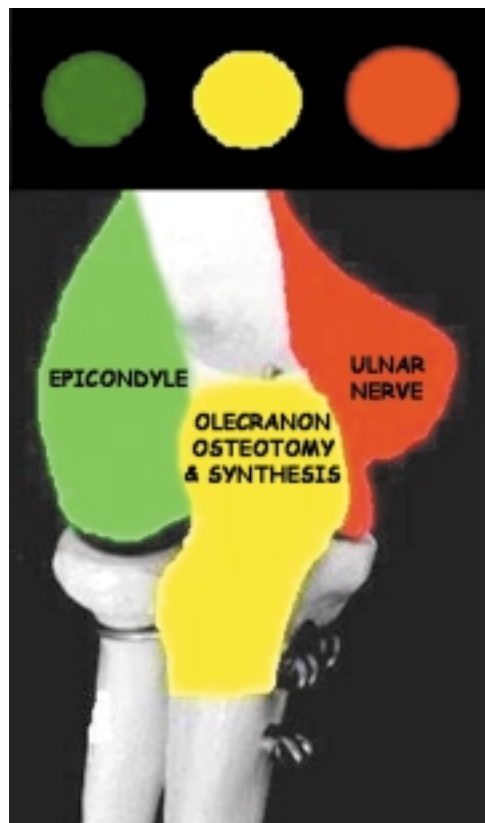

Figure 3. The risks are classified with 3-colours traffic lights model: red light for the ulnar nerve, yellow light for the olecranon osteotomy-osteosynthesis and green light for the lateral side of the joint.

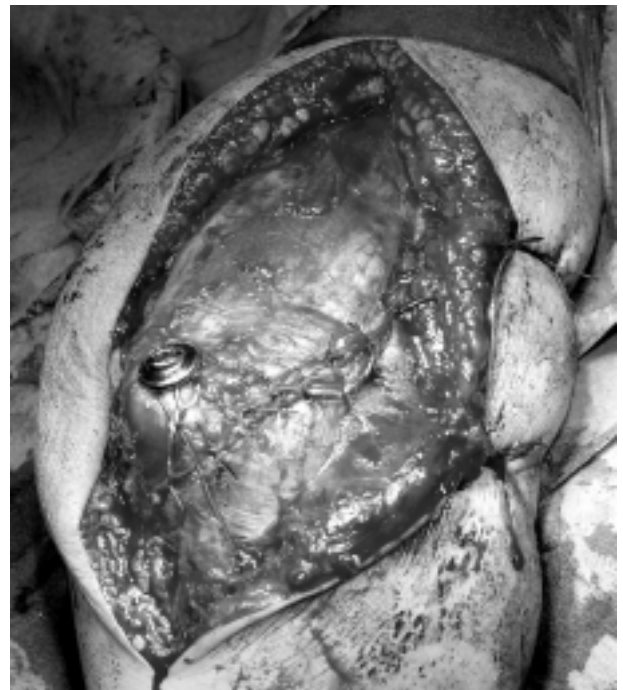

Figure 4. The final result of the closure using the closing screw-washer and cerclage (tension band, also called zuggurtung or haubannage) allows an early and secure elbow mobilization. All risks have been get through.

ribbons and Kocher pincers. At this point the red light becomes yellow and the attention is focused on the olecranon osteotomy, that represents the “yellow light”.

It should be preceded by drilling and reaming for the closing screw. It is preferable to be performed with a “en chevron” shape in order to increase the bony surface for final osteosynthesis and then to prevent undesirable rotary movements so compromising the ulnohumeral function (5). At this point the yellow light becomes green and the attention is focused on the epicondyle, that represents the “green light”. At this level, the incision of the brachialis fascia can be executed with absolute certainty. Once the synthesis of the fracture is performed, the fixation of the transolecranon osteotomy should be done with a 3.2 mm screw-washer with an “8” cerclage in order to achieve sufficient rigidity to allow early motion (6) (Fig. 4).

The essence of this traffic lights model is that every passage must be completed and carefully evaluated before passing to the next one, acquiring control and confidence.

References

1. Shetty S. Surgical treatment of T and Y fractures of the distal humerus. *Injury* 1983;14 (4): 345-8.
2. Wilkinson JM, Stanley D. Posterior surgical approaches to the elbow: a comparative anatomic study. *J Shoulder Elbow Surg* 2001; 10 (4): 380-2.
3. Kinik H, Atalar H, Mergen E. Management of distal humerus fractures in adults. *Arch Orthop Trauma Surg* 1999; 119 (7-8): 467-9.
4. Joshi RP, Yanni O, Gallannaugh SC. A modified posterior approach to the elbow for total elbow replacement. *J Shoulder Elbow Surg* 1999; 8 (6): 606-11.
5. Ring D, Gulotta L, Roy A, Jupiter JB. Concomitant nonunion of the distal humerus and olecranon. *J South Orthop Assoc* 2003; 12 (1): 27-31.
6. Henley MB, Bone LB, Parker B. Operative management of intra-articular fractures of the distal humerus. *J Orthop Trauma* 1987; 1 (1): 24-35.

Accepted in revised form: 17 April 2005

Correspondence: Andrea Salvi, MD

Via Cipro, 30

25124 Brescia

Tel. +39030/220652 - 347/4485570

Fax +39030/220652

E-mail: andrea@orthopaedics.com