

# Endoscopic treatment of esophageal and colo-rectal fistulas with fibrin glue

*Paolo Del Rio, Paolo Dell'Abate, Paolo Soliani, Stefanie Ziegler, Mariafrancesca Arcuri, Mario Sianesi*

Surgical Department General Surgery and Organ Transplantation, University of Parma, Parma, Italy

**Abstract.** So far, the use of fibrin glue has been limited to the treatment of anal, recto-vaginal and entero-cutaneous fistulae. Between 1991 and 2003 we performed the treatment of anastomotic leaks of the upper and lower gastro-intestinal tract with fibrin glue in 13 selected patients. In our experience the treatment with fibrin glue has been proved to be effective in the selected cases. If the fistulae clinically occurred 7 days after surgery a higher number of endoscopic sessions were necessary than in patients with earlier appearance of anastomotic leakage. The utilization of fibrin glue for the endoscopic management of anastomotic leakages after surgery can be successful and safe if applied in selected patients.

**Key words:** fibrin glue, esophageal fistula, colorectal fistula

## Introduction

The incidence of anastomotic dehiscence following gastric and colorectal surgery causes high morbidity and mortality.

The correct pre-operative evaluation, the correction of di-metabolic parameters, the respect of vascularization, and the use of new operative procedures have determined a lower incidence of fistulas in the last 15 years.

Today the treatment of these cases is characterized by a variety of therapeutic options; the endoscopic use of fibrin glue (Tissucol®) should be an option associated with parenteral nutrition

We present our experience of the treatment of gastrointestinal leaks with fibrin glue, from January 1991 to December 2003.

## Materials and methods

From January 1991 to December 2003 we treated 13 cases with endoscopic injection of fibrin glue. Se-

ven patients were affected by esophageal anastomotic fistula and six patients by colorectal leak following low colorectal resection (9 females and 4 males; mean age 57.6 years).

The first group affected by esophageal fistula did not show clinical signs of systemic infection; the leak was drained by a drainage (Chest x-ray pointed out the correct location of drainage).

In the other group with colorectal fistulas, we registered the presence of a low volume fistula (<100 ml/24 hours).

The size of the fistulas after endoscopic and radiologic examination was variable (from 2 to 5 mm diameter) (Fig. 1). In 8 cases the leaks had an early clinical evidence 72 hours after surgical treatment; in 5 cases between 7 and 9 postoperative days.

In all treated cases we followed a strict operative protocol characterized by: radiological evaluation of the fistula; intensive cleaning of the leak by means of physiologic solution; biopsy of the necrotic tissue (antibiogram); antibiotic therapy (in 7 patients we administered ceftriaxone 2 gr x 24 hours and in 6 patients cilastatine+imipenem 1 gr x 3/24 hours); central ve-

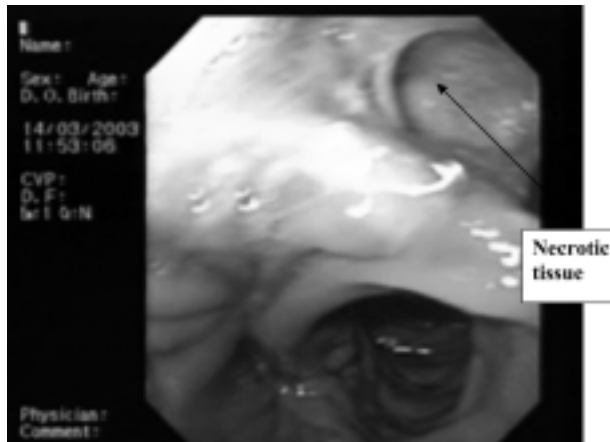


Figure 1. Esophageal fistula: endoscopic preoperative evidence.

nous catheter; parenteral nutrition; radiological examination of drainage location.

The endoscopic technique was performed after i.v. sedation with diazepam (1 ml). We performed a direct injection of fibrin glue around the leak with an injector of 14 gauche and made a submucosal collection in cardinal points to associate the biological action of fibrin glue to the mechanical action of the leak closure.

When we used a single lumen injector we cleaned it with saline solution (1.5-2 ml) before the procedure.

After this step we closed the injector and introduced it in the operative lumen. At this time the injector was open with the introduction of the glue.

When the injector was in the submucosa we injected 0.5 ml of fibrinogenum, 0.7 ml of physiological solution, 0.5 ml of trombin and 2 ml of saline solution. We then extracted it and cleaned the lumen again with 2 ml of saline solution.

The follow-up was carried out by an endoscopic control one and six months following the end of the treatment.

## Results

We have showed a better efficacy in the treatment of the upper gastrointestinal tract respect to the rectal's leak by analyzing clinical signs (fever, leak

Table 1. Clinical cases

N. cases	13 patients	
Sex	7 females	4 males
Mean age	57,6 years	
Type of leak	7 esophago digiunal	6 colorectal (<100 ml/day)
Stay in hospital	All patients were discharged between 12 <sup>th</sup> and 25 <sup>th</sup>	

and radiological examination. The correlation between the surgical procedure and the clinical and radiological signs of complicated leaks is a very important prognostic factor in determining the closure of the leak.

The fistulas that were clinically evident within the 7<sup>th</sup> postoperatively day required a lower number of endoscopic treatments (mean 2.8) compared to the fistulas that appeared after 7 days (mean 3.8).

All patients were discharged between the 12<sup>th</sup> and 25<sup>th</sup> day after endoscopic treatment following a radiological examination without sign of leakage (Tab. 1). No evidence of allergic reactions or systemic/local infections related to the endoscopic treatment with fibrin glue was shown, and the follow up at one and six months did not show any clinical or endoscopic evidence of leakage.

## Discussion

At present the postoperative treatment of upper or lower gastrointestinal fistulas provides many treatments, but no standardized treatment (conservative therapy, endoscopic prosthesis, surgical therapy, etc) can be defined as guideline.

The incidence of dehiscence following surgery, in particular for gastric surgery, has diminished with the use of mechanical suture and the use of parenteral nutrition.

Esophageal leaks have a low incidence but a characteristic high mortality 18-30%.

Some Authors showed that leaks of colorectal tract appear in about 3-5% of all cases (1-5).

These cases showed clinical symptoms such as fever, delayed bowel action, fecal material from the drainage, renal failure, leucocytosis, enhanced coagulation activity and endotoxin concentration in drainage fluid (6, 7).

In literature we can find data that shows if all that patients, surgically treated for low anterior resection, were studied with a radiologic examination with idrosoluble contrast, the incidence of leaks would be higher (9-49%) and an accurate differentiation between anastomosis of high, medium and low rectal tract could be done.

The incidence of leakage significantly depends on the surgical experience of the surgeon (8, 9).

In the last 15 years the endoscopic use of fibrin glue has been mainly used for the conservative treatment of many postsurgical esophageal, gastrointestinal, perineal and rectal-vaginal leaks (10-12).

Fibrin glue is used to support the growth of fibroblasts, stimulated from fibrin, trombin and factor XIII.

At the beginning of this experience the fibrin glue was directly injected into the lumen of the leak with a multiple lumen injector.

During this procedure we must pay a particular attention to the solidification of fibrin glue that can determine the closure of injector. In this case we have to clean the catheter and the endoscopic instrument with saline solution.

We performed this procedure using an injector of 14 gauge only in selective cases, so previously described with respect to the operative protocol.

The result in these treated cases, was a fast recovery in comparison with the conservative treatment (only parenteral nutrition).

Some Authors report a higher percentage of resolution of the fistulas of the upper gastrointestinal tract versus those of the colorectal tract.

The use of this technique is a valid and safe therapeutic option in cases presenting the following characteristics: small dimension of the lumen leak; low leak volume; easy endoscopic treatment; very high anesthesiological and operative risk

Therefore a strict selection of the patients is important for its success.

This endoscopic treatment can be associated with

the traditional method to accelerate the closure of the leaks.

The endoscopist can perform this treatment easily and safely; it is not necessary to be very experienced in this technique because it is based on the use of the needle injector. The risks are very low for the patient and are only referred to the endoscopic procedure.

The cost of fibrin glue is high but the advantage of a shorter hospital stay is significant in reducing the global costs (new surgical procedure, parenteral nutrition, antibiotic therapy, days of hospital stay, etc.). We have found a comparable experience in another center (13) characterized by a lower cost/benefit if compared with the long hospital stay required for other treatments.

In conclusion, our experience showed that the endoscopic use of fibrin glue is easy, safe and can shorten the time of closure of fistula, in selected cases, with an apparent reduction of global costs.

## References

1. Montesani C, De Mito R, Chiappatone S, Narilli P, D'Amato A, Ribotta G. Critical evaluation of the anastomoses in large bowel surgery; experience gained in 553 cases. *Hepato-gastroenterology* 1992; 39: 304-8.
2. Thompson GA, Cocks JR, Collopy BT, et al. Colorectal resection in Victoria. A comparison of hospital based on individual audit. *Aust NZJ Surg* 1996; 66: 520-4.
3. Mella J, Biffin N, Radcliffe AG, Stamatakis JD, Steele RJ. Population based audit of colorectal cancer management in two UK health regions. Colorectal cancer Working Group, Royal College of Surgeons of England Epidemiology and Audit Unit. *Br J Surg* 1997; 84: 1731-6.
4. Ansari MZ, Collopy BT, Hart WG, Carson NJ, Chandraraj EJ. In hospital mortality and associated complications after bowel surgery in Victorian public hospitals. *Aust NZJ Surg* 2000; 70: 6-10.
5. Collopy B. Colorectal anastomotic leak rates are measures of technical skill in surgery. *Aust NZJ Surg* 2001; 71: 508-10.
6. Junger W, Junger WG, Miller K, et al. Early detection of anastomotic leaks after colorectal surgery by measuring endotoxin in the drainage fluid. *Hepatogastroenterology* 1996; 43 (12): 1523-9.
7. Alves A, Panis Y, Pocard M, Regimbeau JM, Valleur P. Management of anastomotic leakage after non diverted larger bowel resection. *J Am Coll Surg* 1999; 189: 554-9.
8. Meagher AP. Colorectal cancer: Is the surgeon a prognostic factor? A systematic review. *Med J Aust* 1999; 171: 308-10.

9. Smedh K, Olsson L, Johansson H, Aberg C, Andersson M. Reduction of postoperative morbidity and mortality in patients with rectal cancer following the introduction of a colorectal unit. *Br J Surg* 2001; 88 (2): 273-7.
10. Groitl H, Horbach T. Endoscopic treatment of anastomosis insufficiency and perforative in the esophagus with fibrin glue. *Langenbecks Arch Chir Suppl Kongressbd* 1996; 113: 753-4.
11. Grund KE, Stuker D. Diagnosis of suture dehiscence in the gastrointestinal tract. Sufficiency of radiology and endoscopy. *Langenbecks Arch Chir Suppl Kongressbd* 1998; 115: 1146-9.
12. Lamont JP, Hooker G, Espenschied JR, Lichliter WE, Franko E. Closure of proximal colorectal fistulas using fibrin sealant. *Am Surg* 2002; 68 (7): 615-8.
13. Testi W, Vernillo R, Spagnulo M, et al. Endoscopic treatment of intestinal anastomotic leak in low anterior resection of the rectum by using fibrin adhesive. Our experience. *Minerva Chir* 2002; 57 (5): 683-8.

Accepted in original form: 22 September 2005

Correspondence: Paolo Del Rio, MD

Surgical Department

General Surgery and Organ Transplantation

University of Parma

Via Gramsci 14

43100 Parma-Italy

Fax +390521992501

E-mail: paolo.delrio@unipr.it