

# Pitfalls and feasibility of a protocol of virtual colonography designed for the screening of colo-rectal pre-cancerous lesions

*Giacomo Luccichenti<sup>1</sup>, Filippo Cademartiri<sup>2</sup>, Lucienne Nogueira<sup>3</sup>, Lorenzo Brambilla<sup>4</sup>, Massimo Gualerzi<sup>1</sup>, Paolo Del Rio<sup>5</sup>, Enrico Foggi<sup>5</sup>, Mario Sianesi<sup>5</sup>, Paolo Coruzzi<sup>1</sup>*

<sup>1</sup>Fondazione Biomedica Europea - ONLUS, Rome, Italy; <sup>2</sup>Department of Radiology, Erasmus Medical Center, Rotterdam, The Netherlands; <sup>3</sup>Centro de Diagnostico por Imagem, Hospital Sirio Libanes, Sao Paulo, Brasil; <sup>4</sup>Unit of Cardiovascular Prevention and Rehabilitation, Fondazione Don C. Gnocchi - ONLUS, University of Parma, Italia; <sup>5</sup>Department of Surgery, University of Parma, Italy

**Abstract.** Purpose: to evaluate the pitfalls occurring during the virtual colonoscopy examination performed with a protocol designed for screening purposes. Materials and methods: 40 patients underwent a spiral CT for virtual colonoscopic evaluation with the following parameters: collimation 3 mm, feed 6 mm.rot<sup>-1</sup>, pitch 2 and increment 1 mm in supine position. Virtual colonography examination was carried out using a dedicated workstation equipped with a software which allows to generate 3D images and virtual endoscopic views. Colon distension, fluid and fecal material were assessed on a 3 point scale. Results: Distension score was 0.50. Left colon and cecum score was 0.32 while in the sigmoid and rectum the score was worse with 0.86. Fluid and fecal residues scores were 0.31 and 0.19 respectively. On almost half of the patients additional scans would be necessary. The main cause of additional scans is suboptimal intestinal preparation and colon distension. Conclusion: The use of virtual colonoscopy for screening purposes will be possible through the further technical development and with the optimisation of the protocols, particularly by the improvement of colon cleansing and distension.

**Key words:** Virtual colonography, computed tomography, screening, colon cancer, polyp

## Introduction

Colon cancer is the second cancer-related cause of death in western countries (1). From several studies, performed to evaluate the efficacy of the removal of adenomatous polyp in the prevention of colon cancer, it is possible to extrapolate a few criteria to build screening programs for this type of cancer (2-4). These criteria are the pre-cancerous nature of adenomatous polyps and the efficacy of their removal in the prevention of colon cancer (5).

The comparison of the results of these studies with epidemiological research suggests the outcome of a large-scale screening programme with removal of colon polyps on the reduction of mortality for this cancer. In fact, a cohort of patients undergoing fiberoptic colonoscopy with immediate removal of polyps would have a reduction of about 76-90% in the incidence of colorectal cancer compared to normal population virtually eliminating mortality for this cancer (4).

The mean estimated period for the growth of a polyp and its further neoplastic transformation is

between 10 and 20 years (6-8). Based on this information, appropriate follow-up intervals are set (9).

From these data it is possible to discuss which method could be able to screen and/or follow-up colorectal polyps. In order to build a screening programme, several aspects need to be accounted for: costs of screening and related treatment, availability of resources in the territory, the population compliance to the tests, radiation protection issues, the sensitivity and specificity of the tests, the actual improvement of prognosis (10-15). Faecal occult blood test, double contrast barium enema, sigmoidoscopy and fiberoptic colonoscopy have been extensively studied for the diagnosis of colo-rectal cancer (4, 16-21). Based on available data, guidelines have been developed, stating that, in a medium risk population, fiberoptic colonoscopy at 10 years intervals is the best strategy from a cost-benefit perspective (5, 8, 11, 12, 14, 22).

Virtual Colonoscopy (VC) is a new technique that allows to obtain a virtual representation of the inner surface of the colon by means of a three-dimensional reconstruction of images obtained from a computed tomography (CT) or a magnetic resonance (MR) scan after distension of colonic walls (23-27). Several studies have already demonstrated the sensitivity and specificity of this technique in the detection of polyps and in the pre-operative evaluation of colon cancer (27-34). Nevertheless, these data have been performed in controlled and optimal research settings, not comparable with a screening environment. Experimental conditions are often far from real radiological practice (35). The rationale of this paper is that, because a screening has to be performed in sub-optimal settings (see above), it is necessary to optimise the VC protocol for the "non-experimental settings" that characterize clinical routine. Therefore, the feasibility of a VC protocol based on CT has been evaluated. Pitfalls and collateral findings affecting the management of the patients have been assessed.

## Materials and Methods

### *Patients*

Forty patients have been prospectively enrolled for VC with CT, between June 2000 and June 2001.

The population (21 males; mean age 61 years; range 25-85 years) has been enrolled outside the Hospital in outpatient settings.

Patients were addressed to our center with different clinical questions: follow-up of endoscopic polypectomy, aspecific colon symptoms, symptoms suspected for colon disease. No patient had a known inflammatory or neoplastic disease of the colon at the moment of the study.

In all cases the patients were carrying a request from the referring physician, who received a flyer containing the information regarding the characteristics, the indications, and the limitations of VC performed with CT. All patients gave written informed consent.

### *Preparation*

Colon preparation was suggested with the letter sent to the referring physician. It was based on 4 envelopes of Selg-esse (Promefarm - Milan - Italy) diluted in 4 liters of water the day before the scan. A three-day low-dross diet was suggested prior to the scan.

The gas distension of the colon was obtained using a Foley catheter (20-26G). The head of the catheter was introduced in the anus by a radiologist with the patient lying on the CT table in left lateral decubitus and bend legs. Once, the head of the catheter was inside for 10 cm the cap was inflated with 15cc of air. Then, the catheter was pulled back to the anus. This last trick was useful to improve anal continence and to allow a better visualisation of eventual rectal masses. Finally, the patient was set in supine position. The scan was performed with spiral CT scanner (Somatom Plus 4, Siemens, Forchheim, Germany).

Once the patient was ready for the scan inside the gantry, 10 mg of Buscopan IV were administered. The insufflation of the colon was started immediately after. When the patient had complaints, the insufflation was stopped for a few seconds. With pain remission, further insufflation was performed up to the tolerance of the patient. At this point a topogram was performed to check the degree of colon distension. If the distension was judged complete the main scan was started otherwise more insufflation was performed. The scan parameters were: collimation 3 mm, feed/rotation

6mm (pitch 2), increment 2 mm, and the scan range between diaphragmatic domes and anus.

### *Image reconstruction and evaluation*

Reconstructed images were sent to a workstation equipped with a dedicated three-dimensional software (Vitrea 2, Vital Images, MN, USA). The evaluation was performed by two observers in consensus with full access to all post-processing tools.

Three main parameters, defining scan quality, were evaluated:

1. Distension (D)
2. Liquid remnants (L)
3. Solid remnants (S)

The observers assigned a score for each parameter to each colon segment (rectum, sigma, descending colon, transverse colon, ascending colon and cecum) using a three-point scale (0; 1; 2). The evaluation was performed following the definitions in table 1.

The evaluation of the overall score of each parameter and of the overall quality of the preparation was calculated with the mean score in each patient. This value was used to compare the parameters. These overall scores (per parameter and overall) ranged between a minimum of 0 (indicating the best performance) and a maximum of 2 (indicating the worst value performance). Collateral extra-colonic findings were recorded and classified (see below).

## Results

### *Patients*

The insufflation was always performed without forcing the patient to resist to the pain due to abdo-

**Table 1.** Scoring parameters and criteria

Score	Distension	Liquid remnants	Solid remnants
0	Optimal	Absent	Absent
1	Sub-optimal, evident folds	Present, non obstructing the lumen	Present, non obstructing the lumen
2	Collapse of the segment	Present, obstructing the lumen	Present, obstructing the lumen

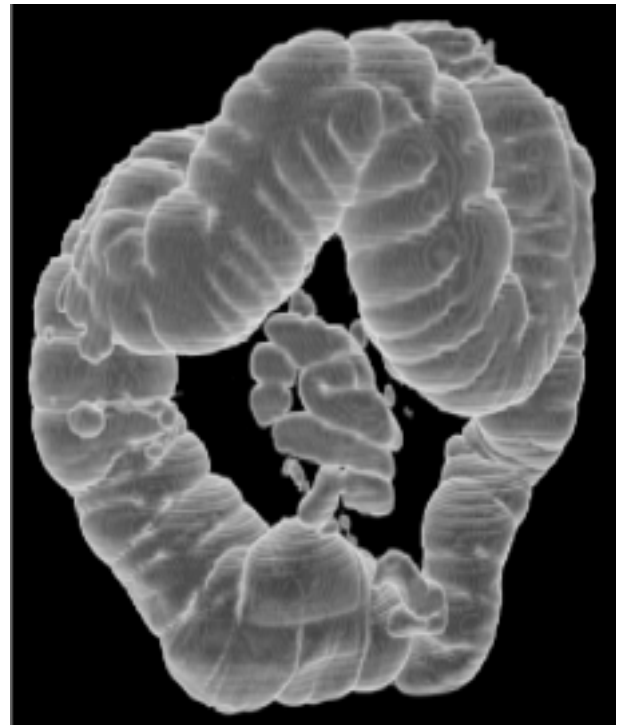minimal and colonic distension. All scans were performed without technical problems.

### *Distension (Figs. 1, 2d)*

The parameter “Distension” had the most asymmetric topography of the three (Fig. 3). The overall score for distension was 0.50. Dis-homogeneities of distension were appraised especially in left colon and cecum with a score of 0.32 while in sigma and rectum the score was 0.86. These segments frequently resulted not well inflated or collapsed.

### *Liquid remnants (Fig. 2a)*

The overall score for liquid remnants was 0.31 and more fluid was observed at the level of sigma/rectum and right colon/cecum (Fig. 4). This fluid distribution inside the colon is gravity-dependent. The sigma/rectum and right colon/cecum are dependent areas



**Figure 1.** Virtual double contrast enema. Three-dimensional reconstruction with volume rendering shows only the interface between air and mucosal surface. In this case an optimal distension of all colonic segments is displayed. The terminal ileum is distended too.

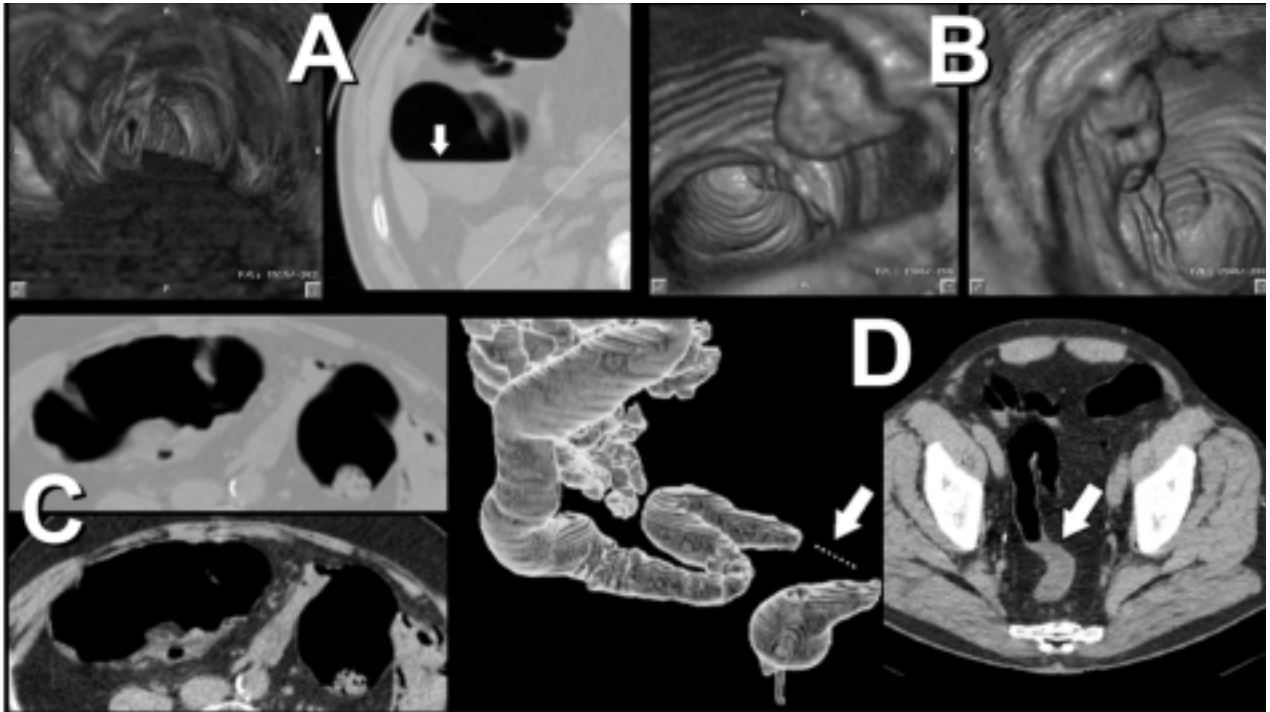


Figure 2. Examples of pitfalls in Virtual Colonoscopy. (a) appearance of liquid levels (arrow) with volume rendering (left image) and on axial images with lung parenchyma window (right image). (b) appearance of solid remnants with volume rendering. Correspondent axial images (c) with soft tissue window (lower image) and lung parenchyma window (upper image), allow to easily rule out the nature of the remnants (note the gas bubbles inside the remnants). (d) example of segmental collapse (arrows) at the level of the sigmoido-rectal junction with volume rendering (left image) and on axial images (right image)

of the colon when the patient is in supine position. If we divide sigma/rectum and right colon/cecum from the remaining part of the colon we obtain a score of 0.36 and 0.23, respectively.

*Solid remnants (Figs. 2b,2c)*

The distribution of solid remnants seems to lack a definite topography (Fig. 5). The overall score for solid remnants was 0.19.

*Overall evaluation*

The overall evaluation of all three parameters was 0.33.

*Specific findings*

Three polyps have been detected in two patients (confirmed by fiberoptic colonoscopy).

*Collateral findings*

The collateral findings were: 3 cases of sigmoido-rectal cancer, one adrenal adenoma, two benign hyper-

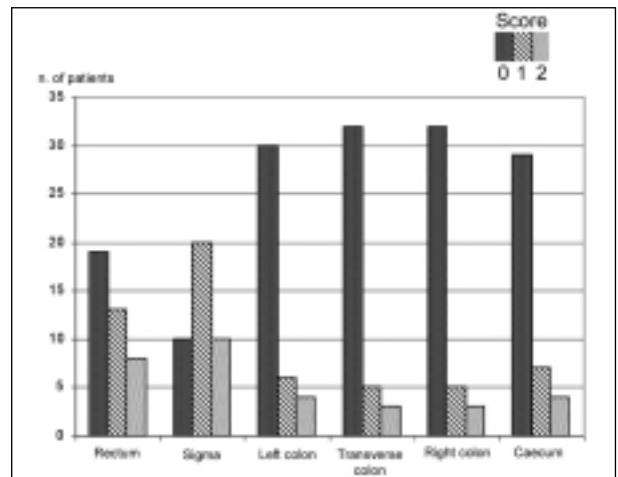


Figure 3. Distension

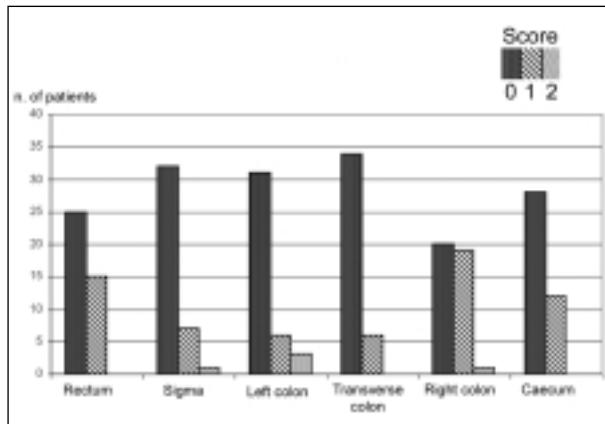


Figure 4. Liquid remnants

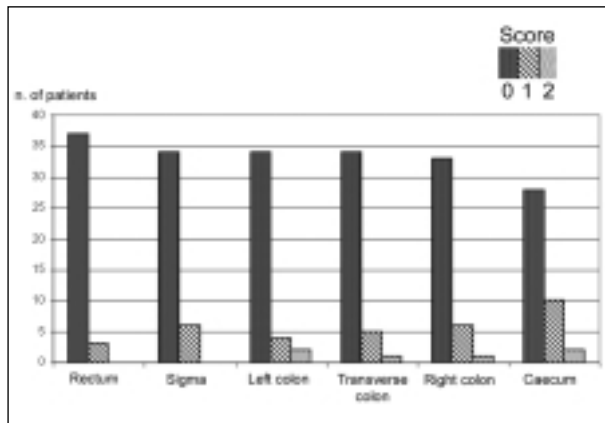


Figure 5. Solid remnants

plastic adrenal glands. Overall, 6 findings, of which 3 benign and 3 malignant, with an incidence of 15% on the population. Those patients underwent a further contrast enhanced CT. All cystic lesions of the kidney were ignored.

## Discussion

Nowadays, the use of VC in the screening of precancerous lesion of the colon is limited by factors related to technique, X-ray exposure, and cost. The pitfalls could be reduced using “State of the Art” scanners, new technologies and eventually additional scans. Nevertheless, the introduction of these techno-

logies increases the management costs of such a screening programme, and it may not solve all issues.

The conditions on which a screening programme with VC should be based seem far from the optimal and those in which this technique has been tested should be controlled with happens in the “real world” of diagnostic screening. For instance, compared to the hospitalised patient, in which bowel preparation and diet can be verified, the outpatient is less compliant and frequently has an inadequate preparation.

Taking into account these two factors (the cost/benefit ratio and the technical feasibility in screening environment), parallel with technical development, it seems necessary to rationalize the protocol/technique. Brachilogically: it is not possible, nor rational, in a screening protocol to perform “everything to everybody”. Therefore, a significant cost and time reduction can be achieved, first reducing the number of scans which means an increased half-life of the X-ray tube and an increase (at least a doubling) of the data to be reconstructed, analysed and archived. This is the rationale of our study based on a single supine scan. The double scan (supine and prone) improves colon distension through the redistribution of fluid and gas in the colon (36-38). Fletcher et al. demonstrated that combining the supine and prone scan the sensitivity for polyp detection significantly improves (39). Nevertheless, this approach can be considered sub-optimal in screening settings. In this perspective, the real question is if the additional costs of an additional scan to the entire screening population are justified as a significantly increased number of polyps has been detected after the first scan (assuming that the diagnosis of further polyps in the additional scan in patients already positive after the first would not change the following diagnostic step).

In the same study it has been reported that additional polyps detected with the double scan were mostly located at the level of sigma and rectum, and that the main explanation for this was segmental collapse, and less perception mistakes (39). The second scan could be avoided with a protocol optimisation able to reduce segmental collapses.

In all the protocols for VC three main phases can be identified: 1) preparation of the patient and colon distension, 2) image acquisition, depending of the

equipment and protocol, 3) data reconstruction and analysis.

The improving, but yet not favourable, cost/benefit ratio of this technique is related to the development of scanners and post-processing tools. These new technologies allow to speed-up phase 2 and 3 of the exam and to partially reduce the pitfalls (the presence of remnants and the inadequate colon distension) occurring in VC and that represent the major limiting factors from the diagnostic point of view. Instead, regarding colon preparation and distension (phase 1), and scan protocol (phase 2), only different algorithms have been compared. It is somewhat surprising the lack of evident improvements (and research) in phase 1 where the main compromising pitfalls occur.

Beside protocol optimisation, another difficult issue to deal with regards the collateral findings. In this paper we identified two different categories of findings, which need an additional scan.

The first category includes intrinsic findings and refers to inadequate distension and/or the presence of liquid or fluid remnants in the colon. The most frequent intrinsic issue in our series was segmental collapse of one or more colon segments and in particular of sigma and rectum (10/40 and 8/40, respectively). Sigmoid collapse can be considered as a major issue because the higher incidence of polyps and cancers occurs at this level (8). Overall, we observed a collapse of one or more segments in 40% of the patients (16/40).

In only 4 patients, liquid remnants were obstructing one or more segments (using a per patient analysis). The segments with more layering of liquid were sigma/rectum and right colon/cecum. To minimize the effect of liquid remnants optimal colon distension becomes mandatory, because it is more likely that a poor amount of liquid will obstruct the lumen if the colon is poorly inflated.

In only 3 patients, solid remnants obstructed one or more segments (using again a per patient approach). Preparation problems were predominantly related to liquid remnants with a score 50% higher compared to solid remnants one (0.31 vs 0.19, respectively). This is in relation to the type of preparation (40). In addition, limitations still remain in the lack of control on patients' compliance in screening settings.

The second category is the extra-colonic findings. These findings are not dependent of the protocol but the type of population enrolled for CV influences their incidence. They can be classified as minor or major depending on the capability of CT to finalize the diagnosis in the same CT session or with additional studies, respectively (example: simple renal cyst vs. solid renal mass). Hara et al. referred the incidence of extra-colonic findings in 41% of the patients, 23% of which (11% of the entire population) were lesions >4 cm of diameter requiring further diagnostic tests, follow-up or surgical procedure (41). In our serie 6 new diseases (15% incidence in the study population) were suspected and diagnosed because of the VC scan. Of those, three were benign and three malignant. It is likely that the use of contrast material would have increased the rate of these findings. Nevertheless, as reported by Morrin et al. who applied contrast enhanced VC for the detection of polyps, the use of contrast material for screening purposes would be too expensive (37).

Using our protocol, at least 42.5% (17/40) and 15% (6/40) of the patients would undergo an additional scan because of intrinsic pitfalls and extra-colonic findings, respectively. These percentages, quiet high at first sight, highlight the following: 1) almost half (14/40) of the population could be screened using only one scan (even though the cost/benefit ratio of the additional scan remains not favourable); 2) the main reasons for an additional scan are preparation and distension (phase 1); 3) patients with extra-colonic findings may need an additional scan. In this case the patient is no more a screening patient, especially with a major extra-colonic finding. Nowadays, it is still controversial if the diagnosis of extra-colonic findings increases or not the expenses for National Health Service (41, 42).

Moreover, research is developing faecal tagging techniques and new software for semi-automated or automated analysis in order to optimise and standardize the diagnostic information of the scan (43-48). An additional scan implies higher maintenance costs but also more data to reconstruct, analyse and archive.

A limitation of this paper could be the use of a single detector spiral CT scanner. The use of multidetector technology has some advantages over single de-

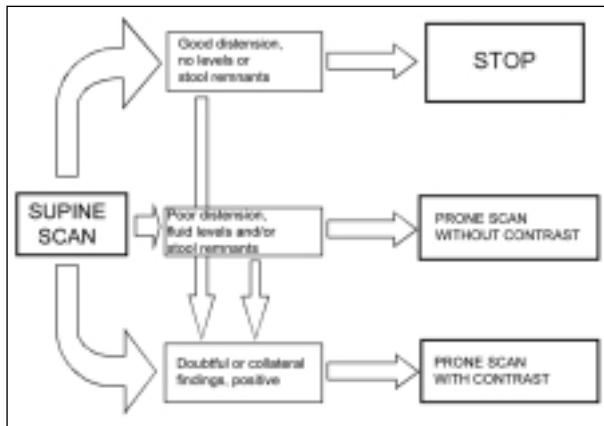


Figure 6. Proposal of algorithm for the application of Virtual Colonoscopy to the screening

tector (49). Nevertheless, in this type of applications, the advantages of multidetector scanner are related to thinner slices and increased scan speed. Both, do not affect the rate of pitfalls due to preparation and moreover they increase the costs even of the first scan. Hara et al. reported a reduction of motion artefacts and sub-optimal distension using a multidetector scanner compared to a single detector (50). Both parameters should improve the efficacy of the single acquisition protocol.

A second limitation is the lack of fiber-optic colonoscopy as gold standard in all patients. Another limitation is the low number of patients. Actually, it was not aim of this paper to evaluate sensitivity and specificity of VC. We wanted, instead, to explore the feasibility and the limitations of a protocol developed for a screening programme (Fig. 6).

In conclusion, the use of CV for screening of precancerous lesions of the colon will become possible using new technologies but also through the rationalization of scan protocols, especially regarding colon preparation and distension.

## References

1. Parker SH, Torrey T, Bolden S, Windigo PA. Cancer statistics 1996. *CA Cancer J Clin* 1996; 65: 5-27.
2. Selby JV, Friedman GD, Quesemberry CP Jr, Weiss NS. A case-control study of screening sigmoidoscopy and mortality from colorectal cancer. *N Engl J Med* 1992; 326: 653-7.

3. Simons BD, Morrison AS, Lev R, Verhoek-Oftedahl W. Relationships of polyps to cancer of the large intestine. *J Natl Cancer Inst* 1992; 84: 962-6.
4. Winawer SJ, Zauber AG, Ho MA, et al. Prevention of colorectal cancer by colonoscopic polypectomy. *N Engl J Med* 1993; 329: 1977-81.
5. Rex DK, Johnson DA, Lieberman DA, et al. Colorectal cancer prevention 2000: screening recommendations of the American College of Gastroenterology. *Am J Gastroenterol* 2000; 95: 868-77.
6. Kozuka S, Nogaki M, Ozeki T, Masumori S. Premalignancy of the mucosal polyp in the large intestine: II. Estimation of the period required for malignant transformation of mucosal polyps. *Dis Colon Rectum* 1975; 18: 494-500.
7. Morson BC. The evolution of colorectal carcinoma. *Clin Radiol* 1984; 35: 425-31.
8. Winawer SJ, Fletcher RH, Miller L, et al. Colorectal cancer screening: clinical guidelines and rationale. *Gastroenterology* 1997; 112: 594-642.
9. Winawer SJ, Zauber AG, O'Brien MJ, et al. Randomized comparison of surveillance intervals after colonoscopic removal of newly diagnosed adenomatous polyps. *N Engl J Med* 1993; 328: 901-7.
10. Frazier AL, Colditz GA, Fuchs CS, Kuntz KM. Cost-effectiveness of screening for colorectal cancer in the general population. *JAMA* 2000; 284: 1954-61.
11. Ness RM, Holmes AM, Klein R, Dittus R. Cost-utility of one-time colonoscopic screening for colorectal cancer at various ages. *Am J Gastroenterol* 2000; 95: 1800-11.
12. Sonnenberg A, Delcò F, Inadomi JM. Cost-effectiveness of colonoscopy in screening for colorectal cancer. *Ann Intern Med* 2000; 133: 573-84.
13. Loeve F, Brown ML, Boer R, et al. Endoscopic colorectal cancer screening: a cost-saving analysis. *J Natl Cancer Inst* 2000; 92: 557-63.
14. American Society for Gastrointestinal Endoscopy. Guidelines for colorectal cancer screening and surveillance. *Gastrointest Endosc* 2000; 51: 777-81.
15. Obuchovsky NA, Graham RJ, Baker ME, Powell KA. Ten criteria for effective screening: their application to multislice CT screening for pulmonary and colorectal cancers. *AJR Am J Roentgenol* 2001; 176: 1357-62.
16. Mandel JS, Bond JH, Church TR, et al. Reducing mortality from colorectal cancer by screening for fecal occult blood. *N Engl J Med* 1993; 328: 1365-71.
17. Winawer SJ, Flehinger BJ, Schottenfeld D, et al. Screening for colorectal cancer with faecal blood testing and sigmoidoscopy. *J Natl Cancer Inst* 1993; 85: 1311-8.
18. Ahlquist DA, Wieand HS, Moertel CG, et al. Accuracy of fecal occult blood screening for colorectal neoplasia. *JAMA* 1993; 269: 1262-7.
19. Mandel JS, Church TR, Bond JH, et al. The effect of fecal occult-blood screening on the incidence of colorectal cancer. *N Engl J Med* 2000; 343: 1603-7.
20. Winawer SJ, Steward ET, Zauber AG, et al. A comparison of colonoscopy and double-contrast barium enema for surveillance after polypectomy. *N Engl J Med* 2000; 342: 1766-72.

21. Lieberman DA, Weiss DG. One-time screening for colorectal cancer with combined fecal occult-blood testing and examination of the distal colon. *N Engl J Med* 2001; 345: 555-60.
22. Brenner H, Arndt V, Stürmer T, et al. Long-lasting reduction of risk of colorectal cancer following screening examination. *Br J Cancer* 2001; 85: 972-6.
23. Vining DJ, Shifrin RY, Grishaw EK, et al. Virtual colonoscopy. 80th RSNA. *Radiology* 1994; 193: 446.
24. Vining DJ, Gelfand DW, Bechtold RE, et al. Technical feasibility of colon imaging with helical CT and virtual reality. *AJR Am J Roentgenol* (abs) 1994; 162: S104.
25. Hara AK, Johnson CD, Reed JE, et al. Detection of colorectal polyps by computed tomographic colonography: feasibility of a novel technique. *Gastroenterology* 1996; 110: 284-90.
26. Pavone P, Laghi A, Panebianco V, et al. Virtual endoscopy with a volumetric reconstruction technique: the technical aspects. *Radiol Med (Torino)* 1998; 95: 618-23.
27. Johnson CD, Dachman AH. CT colonography: the next colon screening examination? *Radiology* 2000; 216: 331-41.
28. Hara AK, Johnson CD, Reed JE, et al. Detection of colorectal polyps with CT colonography: initial assessment of sensitivity and specificity. *Radiology* 1997; 205: 59-65.
29. Fenlon HM, Nunes DP, Schroy PC 3rd, et al. A comparison of virtual and conventional colonoscopy for the detection of colorectal polyps. *N Engl J Med* 1999; 341: 1496-503.
30. Fenlon HM, McAneny DB, Nunes DP, et al. Occlusive colon carcinoma: virtual colonoscopy in the preoperative evaluation of the proximal colon. *Radiology* 1999; 210: 423-8.
31. Morra A, Meduri S, Ammar L, et al. Colonoscopy with computed tomography with volume reconstruction. The results and comparison with endoscopy and surgery. *Radiol Med (Torino)* 1999; 98: 62-7.
32. Rex DK, Vining D, Kopecky KK. An initial experience with screening for colon polyps using spiral CT with and without CT colonography (virtual colonoscopy) *Gastrointest Endosc* 1999; 50: 309-13.
33. Regge D, Galatola G, Martincich L, et al. Use of virtual endoscopy with computerized tomography in the identification of colorectal neoplasms. Prospective study with symptomatic patients. *Radiol Med (Torino)* 2000; 99: 449-55.
34. Yee J, Akerkar GA, Hung RK, et al. Colorectal neoplasia: performance characteristics of CT colonography for detection in 300 patients. *Radiology* 2001; 219: 685-92.
35. Hunink MGM, Krestin GP. Study design for concurrent development, assessment, and implementation of new diagnostic imaging technology. *Radiology* 2002; 222: 604-14.
36. Chen SC, Lu DS, Hecht JR, Kadell BM. CT colonography: value of scanning in both the supine and prone positions. *AJR Am J Roentgenol* 1999; 172: 595-9.
37. Morrin MM, Farrel RJ, Kruskal JB, et al. Utility of intravenously administered contrast material at CT colonography. *Radiology* 2000; 217: 765-71.
38. Morrin MM, Farrel RJ, Keogan MT, et al. CT colonography: colonic distension improved by dual positioning but not intravenous glucagons. *Europ Radiol* 2002; 12: 525-30.
39. Fletcher JG, Johnson CD, Welch TJ, et al. Optimization of CT colonography technique: prospective trial in 180 patients. *Radiology* 2000; 216: 704-11.
40. Macari M, Lavelle M, Pedrosa I, et al. Effect of different bowel preparations on residual fluid at CT colonography. *Radiology* 2001; 218: 274-7.
41. Hara AK, Johnson CD, MacCarty RL, Welch TJ. Incidental extracolonic findings at CT colonography. *Radiology* 2000; 215: 353-7.
42. Edwards JT, Wood CJ, Mendelson RM, Forbes GM. Extracolonic findings at virtual colonoscopy: implication for screening programs. *Am J Gastroenterol* 2001; 96: 3009-12.
43. Sheppard DG, Iyer RB, Herron D, Charnsangavej C. Subtraction CT colonography: feasibility in an animal model. *Clin Radiol* 1999; 54: 126-32.
44. Weishaupt D, Patak MA, Froehlich J, et al. Faecal tagging to avoid colonic cleansing before MRI colonography. *Lancet* 1999; 354: 835-6.
45. Callstrom MR, Johnson CD, Fletcher JG, et al. CT colonography without cathartic preparation: feasibility study. *Radiology* 2001; 219: 693-8.
46. Masutani Y, Yoshida H, MacEaney PM, Dachman AH. Automated segmentation of colonic walls for computerized detection of polyps in CT colonography. *J Comput Assist Tomogr* 2001; 25: 629-38.
47. Summers RM, Johnson CD, Pusanik LM, et al. Automated polyp detection at CT colonography: feasibility assessment in a human population. *Radiology* 2001; 219: 51-9.
48. Yoshida H, Masutani Y, MacEaney P, et al. Computerized detection of colonic polyps at CT colonography on the basis of volumetric features: pilot study. *Radiology* 2002; 222: 327-36.
49. Laghi A, Catalano C, Panebianco V, et al. Optimization of the technique of virtual colonoscopy using a multislice spiral computerized tomography. *Radiol Med (Torino)* 2000; 100: 459-64.
50. Hara AK, Johnson CD, MacCarty RL, et al. CT colonography: single- versus multidetector row imaging. *Radiology* 2001; 219: 461-5.

Received: 29 Genuary 2004

Accepted: 24 February 2005

Correspondence: Dr. Filippo Cademartiri

Viale Rustici, 2

43100 - Parma

Tel. 0521 961833

E-mail: filippocademartiri@hotmail.com