

## Giant fibroma of the lesser omentum: report of a rare case

*Domenico Iusco, Enrico Donadei, Giuseppe Sgobba, Leopoldo Sarli*

Surgical Department, Section of Surgical Clinic and Surgical Therapy, University of Parma, Italy

**Abstract.** We report a case of a 43 years old male that presented to emergency room for epigastric and mesogastric pain associated with a palpable abdominal mass. Explorative laparotomy showed a well capsulated tumour of the lesser omentum, sized 20 x 16 x 10cm. Histologically the mass was characterized by thick fibrous capsula, with areas of moderate cellularity alternated to areas of sclerosis, spots of hemorrhagies and infarctual necrosis, spindle-shaped cells within collagen bundles that did not present mitotic activity or atypies and showed a low proliferation index with Ki 67 and histochemical positivity for CD 34 and negativity for C-Kit, anti-smooth cell and S100 antigen. Final diagnosis: solitary fibroma of the lesser omentum. To our knowledge only one case of lesser omentum fibroma has been reported in literature.

**Key words:** lesser omentum, giant fibroma, thick fibrous capsula

### Introduction

Primary tumours of the lesser omentum are rare, and this rarity may account for the paucity of information in basic texts and in literature (1-5). To our knowledge fibroma of the lesser omentum has been described in only one case (6).

We present a case of lesser omentum giant fibroma and discuss the different diagnostic possibilities that should be taken in consideration when facing a mass of the lesser omentum.

### Case Report

B.R. 43 years-old male was admitted in our emergency room service for hepigastric and mesogastric abdominal pain and fever. The remote pathological anamnesis showed aortic bicuspidism for which the patient was under strict cardiologic control. At physical examination the patient presented tenderness of the abdomen with a palpable 9 x 18 cm periombel-

lical mass that reached the hepigastric region. Serological exam showed leucocytosis  $17 \times 10^3/\mu\text{L}$ . US examination showed a solid abdominal mass 20 x 16 x 10 cm of diameter with disomogenic hyperechogenicity. Contrast enhanced CT showed a 20 x 16 x 10 cm mass with disomogenic structure with peripheral contrast enhancement more expressed in the left portion of the mass, apparently intraperitoneal in contact with the stomach and the first portion of the duodenum (Figure 1). In the most cranial portion of the mass it was possible to notice serpiginous stripes with perilesional adipose tissue suspect for infiltration.

EGDS performed for suspected primitive tumour of the stomach was negative for gastric and duodenal lesions.

The patient underwent explorative laparotomy that showed a well capsulated tumour of the lesser omentum, slightly adherent to the stomach. The mass was removed without difficulty. Macroscopically this mass was covered with a thin layer of adipose tissue, it showed a white cut surface with some black spots and the consistence of wood (Figure 2). Histologically, the

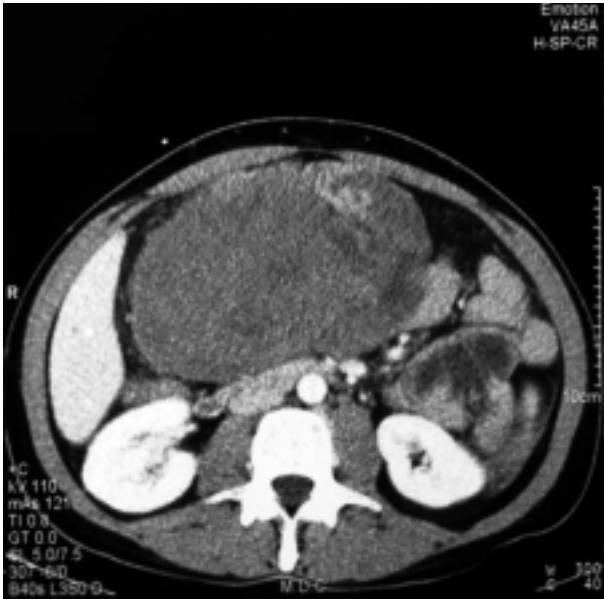


Figure 1. CT showing the intraperitoneal mass with disomogenic structure with peripheral contrast enhancement more expressed in the left portion of the mass

tumour was composed of a thick fibrous capsula, a fascicular structure with areas of moderate cellularity alternated to areas of sclerosis, with spots of hemorrhages and infarctual necrosis. The tumoral cells were spindle-shaped cells within collagen bundles, and did not present mitotic activity or atypies and showed a low proliferation index with Ki 67 (18,3%). They showed histochemical positivity for CD 34 and negativity for C-Kit, anti-smooth cell and S100 antigen. Final diagnosis: solitary fibroma of the lesser omentum.

The patient had an uneventful post-operative course and was free of recurrence at 1 year follow-up.

## Discussion

Fibromas are well-circumscribed tumors consisting of dense collagen bundles and variable number of mature fibroblast. They are usually small tumours that are firm, encapsulated and pearly gray on cross section (7).

Despite the widespread distribution of connective tissue throughout the body fibromas are surprisingly limited in their origin. Infact while fibroma of ten-

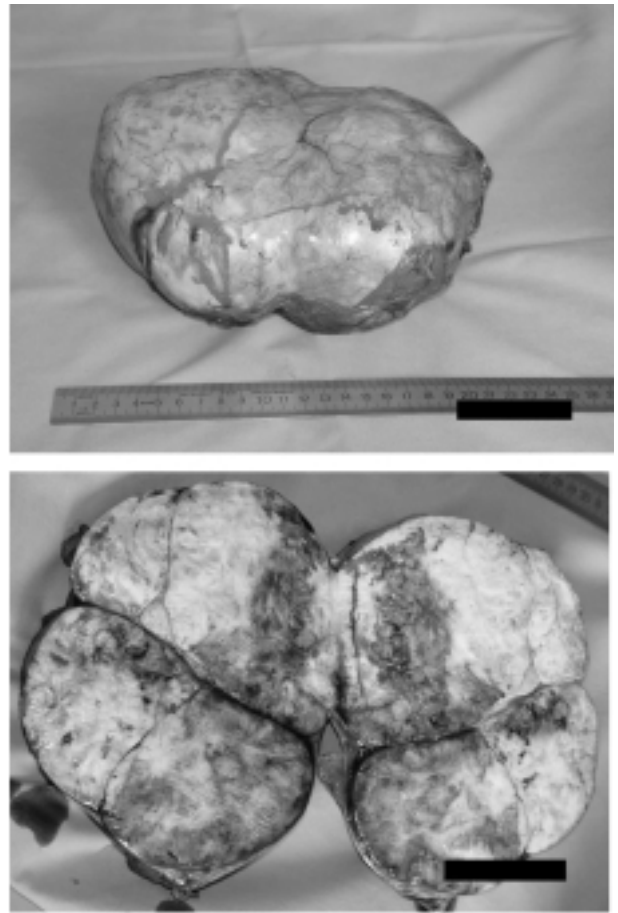


Figure 2. Picture showing the surgical specimen and its cut surface

don sheath, for example, is a comparatively common tumour, the incidence of omental fibroma is not known (8). This is surely due to its rarity, and despite the frequent use of non invasive imaging, the number of incidental findings of these tumors remains low (9). In english litterature only one case of lesser omentum fibroma has been reported before our observation (6). Symptoms in both cases were are epigastric fullness, tenderness, pain and episode of vomiting. US and CT scan resulted in both cases fundamental to study the lesions. Even if some radiological characteristic may be peculiar, for example multiple cystic areas and enhancement of solid areas in leiomyosarcomas on CT, it is usually very difficult to make a pre-operative diagnosis only with radiological examination.

At present, there are no objective data in the literature to support or to deny the performance of fine-

needle biopsy of an omental tumour before omentectomy (9).

Surgical resection is the only method of management not only for histologic diagnosis, but also for curative treatment since fibroma rarely recurs and never develop metastasis (8).

## References

1. Stout AP, Hendry J, Purdie FJ. Primary solid tumors of the great omentum. *Cancer* 1963; 16: 231-43.
2. Elfving G, Hastbacka J. Primary solid tumours of the greater omentum. *Acta Chir Scand* 1965; 130: 603-10.
3. Huckman MS, Fisher MS. Roentgenographic signs of tumours of the greater omentum. *Cancer* 1974; 33: 1526-30.
4. Weinberger HA, Ahmed MS. Mesenchymal solid tumours of the omentum and mesentery: report of four cases. *Surgery* 1977; 82: 754-9.
5. Tanimura A, Cho T, Nohara M, et al. Primary leiomyosarcoma of the omentum. *Kurume Med J* 1980; 27: 101-5.
6. Paksoy Y, Sahin M, Acikgozoglul S, Odev K, Omeroglu E. Omental fibroma: CT and US findings. *Eur Radiol* 1998; 8: 1422-4.
7. Rosemberg AE. Skeletal system and soft tissue tumors. In: Cotran RS, Kumar V, Robbins LS (eds) *Pathologic basis of diseases*. Saunders, Philadelphia, 1994.
8. Enzinger FM, Weiss SW. Benign tumours and tumours-like lesions of fibrous tissue. In: Enzinger FM (ed) *Textbook of soft tissue tumours*. 1988 Mosby, Washington DC, 102-131.
9. Ishida H, Ishida J. Primary tumours of the greater omentum. *Eur Radiol* 1998; 8: 1598-601.

Received: 9 March 2004

Accepted: 4 March 2005

Correspondence: Iusco Domenico, MD

Istituto Clinica Chirurgia Generale e Terapia Chirurgica,

Azienda Ospedale,

Via Gramsci n. 14,

43100 Parma, Italy

Tel: 0039.521.702156

Fax 0039.521.940125

E-mail: minguccio73@hotmail.com