

Albright's Hereditary Osteodystrophy (Pseudohypoparathyroidism Type Ia): clinical case with a novel mutation of GNAS1

Livia Garavelli¹, S. Padori², C. Zanacca¹, G. Caselli¹, A. Loiodice¹, G. Mantovan², A. Ammenti³, Raffaele Viridis³, G. Banchini¹

¹Department of Pediatrics S. Maria Nuova Hospital, Reggio Emilia, Italy; ²Institute of Endocrine Science, University of Milan, Ospedale Maggiore IRCCS, Milan, Italy; ³Department of Pediatrics, Parma University, Parma, Italy

Abstract. Albright's hereditary osteodystrophy is characterized by ectopic calcification and ossification, round face, short hands and feet with short terminal phalanges, short metacarpals (especially 4th and 5th) and absence of the 4th knuckle (brachydactyly type E) [1]. Here we describe a case that recently came to our attention of a girl suffering from seizures caused by hypocalcaemia, in which the clinical diagnosis of Albright's hereditary osteodystrophy and Pseudohypoparathyroidism (PHP) (Pseudohypoparathyroidism Ia) was confirmed by DNA molecular analysis. This analysis revealed a novel mutation of GNAS1, resulting in the nonsense mutation of exon 13 (CAG→TAG, codon 384). This result expands the spectrum of GNAS1 mutations associated with this disorder.

Key words: Albright's Hereditary Osteodystrophy, Pseudohypoparathyroidism, PPHP, Type IA, GNAS1, nonsense mutation of exon 13 (CAG→TAG, codon 384)

Introduction

Pseudohypoparathyroidism (PHP) is a heterogeneous group of disorders whose common feature is parathyroid hormone resistance (PTH). It is generally classified as types Ia, Ib, Ic, and II according to different phenotypes and pathogenesis (2). Albright's hereditary osteodystrophy (AHO) is a syndrome characterized by several distinct physical features, including short stature, obesity, round facies, subcutaneous ossifications, brachydactyly, and other skeletal anomalies (2). Some patients have mental retardation. AHO is often associated with pseudohypoparathyroidism, hypocalcemia, and elevated PTH levels (PHP Ia). Patients with pseudopseudohypoparathyroidism (PPHP) have normal calcium metabolism and PTH levels with

isolated AHO (3, 4). Mutations of the GNAS1 gene, which is located on chromosome 20q13-11 and encodes the α -subunit of the stimulatory GTP-binding protein, have been identified in patients with pseudohypoparathyroidism type Ia (PHP1a) and pseudopseudohypoparathyroidism (PPHP) (5-9). Both autosomal dominant inherited disorders can occur in the same family. It has been recognized that in the case of maternal transmission the children develop PHP1a; on the other hand, if the mutation is derived from the father, the children develop PPHP. This parental origin effect has led to the suggestion of Gs α imprinting (10). The coding region of the human Gs α gene GNAS1 is divided into 13 exons; however, additional exons and alternative splicing products have been described. During the last years around 35 different inac-

tivating mutations in the *GNAS1* gene have been identified in patients with AHO and PHP or PPHP (6-9). This case report describes a patient with a novel mutation of *GNAS1*, resulting in the nonsense mutation of exon 13 (CAG→TAG, codon 384). This result expands the spectrum of *GNAS1* mutations associated with this disorder.

Clinical report

The patient was born at the 40th week of gestation from healthy non-consanguineous parents (19 year-old mother and 20 year-old father). In the family there was no record of hypocalcemia and brachydactyly. The pregnancy was unremarkable without known exposure to potential teratogens. The fetal movements were normal. The patient was born by vaginal delivery with a birth weight of 3420 g. Apgar scores were 3 and 7 at 1 and 5 minutes, respectively. She was admitted to the Neonatological Intensive Care Unit for 5 days. The psychomotor development was normal. Her first tooth appeared at the age of twelve months. She was referred to us because of seizures brought on by hypocalcaemia.

Laboratory tests on admission revealed hypocalcaemia (5.7 mg/dl) with ionized calcium 0,1 mmol/l, hyperphosphatemia (9.3 mg/dl) and elevated serum parathyroid hormone (PTH) level (415 pg/ml). She had hypothyroidism : FT3 3.6 pg/ml, FT4 9,2 pg/ml, TSH 14.18 microU/ml. Investigations including 25-OH Vitamin D, calcitonin, urinary phosphate, urinary calcium, AGA, EMA, tTG, anti-tyreoglobuline antibodies, anti-peroxidase antibodies and FISH analysis for 22q11.2 deletion were all normal. Her ophthalmologic evaluation, ECG, abdominal ultrasound, thyroid ultrasound and EEG were also all normal.

On examination (Fig. 1) her head circumference was 50 cm (50th centile), height 96 cm (10th centile), weight 17.200 Kg (75th centile), total right hand length 11 cm (25th-50th centile), palm length 6 cm, total left hand length 10,1 cm (25th-50th centile), palm length 6 cm. Pubertal development (Tanner) was A0P1B1. She had round face, horizontal palpebral fissures, posteriorly rotated ears, brachydactyly type E (IV and V metacarpals) and genu valgum.

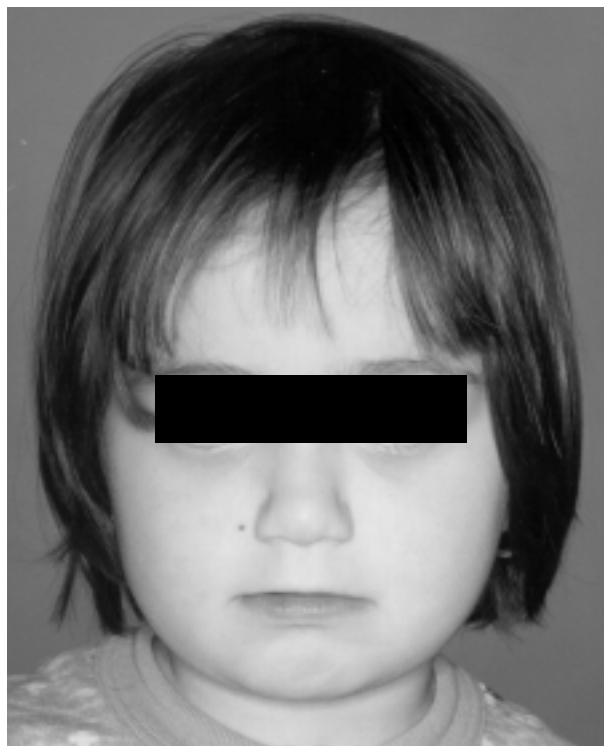

Figure 1. Craniofacial phenotype

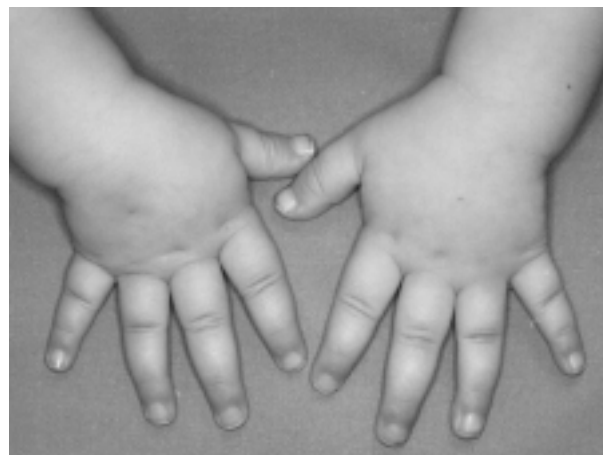

Figure 2. Hand

The skeletal survey showed normal bone age, brachydactyly, short metacarpals, especially 4th and 5th and osteoporosis. Cranial CT scan demonstrated basal ganglion calcification. We considered these clinical findings sufficient for the diagnosis of Albright's hereditary osteodystrophy (Pseudohypoparathyroidism ty-

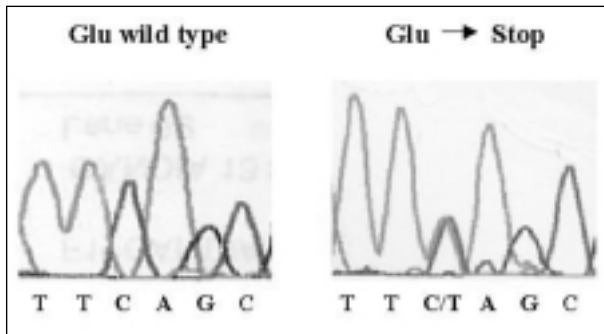


Figure 3. Mutation analysis

pe Ia OMIM 103580) (2). Genomic DNA was extracted with phenol-chloroform method from her peripheral blood leucocytes (Nucleon-Amersham Life Science, England). The *Gsa* gene (exons 1-13, GenBank accession no.AH002748) was then amplified by polymerase chain reaction (PCR) using the specific primers previously described (6). Direct sequencing of the amplified fragments was then performed using the AmpliTaq BigDye Terminator kit and 310 Genetic Analyzer (Perkin Elmer Corp., Applied Biosystems, Foster City, CA). By this approach, we have identified a novel, never described mutation in the *GNAS1* gene: this was a heterozygous non-sense mutation in exon 13: CAG→TAG codon 384 (Fig. 3).

The girl started intravenous calcium and subsequently oral and thyroxin treatment; milk intake was reduced and dairy products eliminated from her diet. Four months after diagnosis calcium levels and thyroid function returned to normality and plasma phosphorus was within acceptable levels.

Discussion

The main clinical features of our patient include:

- Late dental development
- Phenotype characterized by round face, slight type E brachydactyly, genu valgum
- Seizures due to hypocalcaemia and hyper-phosphatemia
- Significant increase of PTH: 415 pg/ml
- Hypothyroidism
- Brain calcifications

The clinical features aforementioned brought us to suspect this condition, which must be taken into consideration in the differential diagnosis of hypocalcaemia. Furthermore our case presents particular interest since the detected mutation is unknown in scientific literature and causes a precocious stop-codon, giving rise to a truncated protein. The type 1a Pseudohypoparathyroidism (PHP 1a) is caused by a defect of α sub-unit of Gs i.e. stimulatory guanine nucleotide-binding protein of adenylate cyclase (5). The gene for the α sub-unit of Gs (*GNAS1*) has been mapped on the long arm of chromosome 20 and contains 13 exons. Mutations have been localized in the entire coding region of the gene, each mutation being usually associated to a single kindred. All exons can be affected by alterations that cause loss of function, with the exception of exon 3, where no mutations have been detected to date. The activity of the G unit is 50% in PHP 1a and 100% in PHP 1b. AHO clinical manifestations can be differentiated by the presence (PHP1a and PHP1c) or absence (PHP1b) of resistance to hormones other than PTH that act via Gs coupled receptors, such as TSH and gonadotropins (7) (Tab. 1). All cases of PHP1a, PHP1b and PHP1c have renal resistance at PTH, but thyroid resistance at TSH, liver resistance at the glucagons and gonadic dysfunction which may be observed in most cases of PHP 1a are very rare in PHP 1b.

In patients in whom the activity of the Gs protein has been determined, 9 out of 14 patients with PHP 1a and none of the 11 patients with PHP 1b had mental retardation (12). The published cases of Albright's hereditary osteodystrophy show a marked excess of maternal transmission. Furthermore the full expression of the gene (Albright's osteodystrophy plus hormonal resistance) is evident in the maternally transmitted cases, while only a partial expression is observed in the

Table 1. Pseudohypoparathyroidism classification (from Lamia et al., 2001)

	AHO	Hormone resistance	<i>GNAS1</i> defect
PHP1a	Yes	Multiple	Yes
PPHP	Yes	None	Yes
PHP1b	No	PTH	Yes
PHP1c	Yes	Multiple	No
PHPII	No	PTH	No

paternally transmitted ones (10). These observations provide evidence that the variable and tissue-specific hormone resistance observed in PHP Ia may result from tissue-specific imprinting of the GNAS1 gene. However the involvement of genomic imprinting has not yet been demonstrated (13). It is important to carry out the molecular analysis in the parents, particularly in the mother (6-9). We conclude that molecular analysis of GNAS1 can be a valuable tool in confirming the diagnosis of AHO.

Acknowledgements

The authors wish to thank the co-operating family-members for the necessary medical data and photographs for publication. Furthermore we wish to thank Marco Bonazzi e Amos Rainieri for their excellent photographs.

References

- Weinberg AG, Stone RT. Autosomal dominant inheritance in Albright's hereditary osteodystrophy. *J Pediat* 1971; 79: 996-9.
- OMIM Online Mendelian Inheritance in man <http://www.ncbi.nlm.nih.gov/htbin-post/Omim/dispim?103580>
- Kinard RE, Walton JE, Buckwalter JA. Pseudohypoparathyroidism. *Arch Intern Med* 1979; 139: 204-7.
- Fitch N Albright's hereditary osteodystrophy: a review. *Am J Med Genet* 1982; 11: 11-29.
- Levine MA, Anh TG, Klupt SF, et al. Genetic deficiency of the alpha subunit of the guanine nucleotide-binding protein G(s) as the molecular basis for Albright hereditary osteodystrophy. *Proc Nat Acad Sci* 1988; 85: 617-21.
- Mantovani G, Romoli R, Weber G, et al. Mutational analysis of GNAS1 in patients with pseudohypoparathyroidism: identification of two novel mutations. *J Clin Endocrinol Metab* 2000; 85: 4243-8.
- Lania A, Mantovani G, Spada A. G protein mutations in endocrine diseases *Eur J Endocrinol* 2001; 145: 543-59.
- Ahmed SF, Dixon PH, Bonthron DT, et al. GNAS1 mutational analysis in pseudohypoparathyroidism. *Clin Endocrinol* 1998; 49: 525-31.
- Ahrens W, Hiort O, Kirschner T, Marschke C, Kruse K. Analysis of the GNAS1 gene in Albright's hereditary Osteodystrophy. *J Clin Endocrinol Metab* 2001; 86 (10): 4630-4.
- Davies SJ, Hughes HE. Imprinting in Albright's hereditary osteodystrophy. *J Med Genet* 1993; 30: 101-3.
- Stryer L, Bourne HR. Gproteins: a family of signal transducers. *Annu Rev Cell Biol* 1986; 2: 391-419.
- Farfel Z, Friedman E. Mental deficiency in pseudohypoparathyroidism type I is associated with Ns-protein deficiency *Ann Intern Med* 1986; 105: 197-9.
- Wilson LC, Oude Luttikhuis MEM, Clayton PT, Fraser WD, Trembath RC. Parental origin of Gs-alpha gene mutations in Albright's hereditary osteodystrophy. *J Med Genet* 1994; 31:835-9.

Received: 26 April 2004

Accepted: 29 March 2005

Correspondence: Dr. Livia Garavelli

Dipartimento Materno-Infantile,

Unità Operativa di Pediatria,

Ambulatorio di Genetica Clinica,

Arcispedale S. Maria Nuova - Azienda Ospedaliera

Viale Risorgimento, 80 42100 Reggio Emilia, Italy

Tel. 0039-0522-296244/296241

Fax 0039-0522-295934

E mail: garavelli.livia@asmn.re.it