

Video assisted thoracoscopy in thoracic injury: early or delayed indication?

*Duilio Divisi**, *Carmelo Battaglia**, *Berardo De Berardis***, *Maurizio Vaccarili**, *William Di Francescantonio**, *Salvatore Salvemini**, *Roberto Crisci**

* Department of Thoracic Surgery, University of L'Aquila - "G. Mazzini" Hospital, Piazza Italia 1, 64100 Teramo (Italy).

** Department of General Surgery, "G. Mazzini" Hospital, Piazza Italia 1, 64100 Teramo (Italy).

Abstract. The aim of this study was to evaluate the diagnostic role and therapeutic effectiveness of videothoracoscopy in chest trauma. Between 1st January 1993 and 30th September 2003, 112 traumatized patients underwent a videothoracoscopy. The origin of trauma was different : 60 road accidents, 42 accidental falls, 7 knife wounds and 3 firearm wounds. Seventy-six patients presented hemothorax, 21 hemopneumothorax, 10 suspected diaphragmatic injury and 5 pericardium effusion. All patients were hemodynamically stable and conscious. In suspected diaphragmatic rupture patients, videothoracoscopy confirmed the presence of 4 lesions with diameter from 7 to 10cm. The etiopathogenetic causes in the other clinical patterns were: 20 lung lacerations, 17 apical adhesion lacerations, 11 diaphragmatic lesions, 16 wall bleedings and 38 vessel lesions. Ninety patients (80.3%) were treated with video assisted thoracic surgery. The remaining procedures were : 17 drainage tube insertions, 4 thoracotomies and 1 laparotomy. Videothoracoscopy made the use of the primary intention drainage tube obsolete in stable traumatized patients with hemothorax or hemopneumothorax. It is a safe technique that allows the diagnostic and surgical management of the lesions.

Key words: Chest trauma, hemothorax, hemopneumothorax, diaphragmatic injury; video assisted thoracic surgery

Introduction

Video assisted thoracoscopy (VAT) has acquired specific indications in some cases representing the surgical standard (VATS), but its role in chest traumas remains controversial. Our group, in a preliminary study, proposed the use of VAT in thoracic injury (5). Such approach is practicable in patients who do not present an imposing politrauma or critical conditions, and are in a state of consciousness and circulatory stability. Ideal situations are hemothorax and hemopneumothorax, besides piercing wounds resulting from firearms and knives. The advantages of videothoracoscopy treatment in hemothorax compared to classic drainage-and-waiting are to be ascribed

over all due to the immediacy of the possible passage from a diagnostic thoracoscopy to the operative thoracoscopy realizing a hemostasis of minimum or intense hemorrhaging. On the other hand, even in cases in which it might not be necessary to proceed to hemostasis, VAT obtains the result of evacuating the pleural cavity completely of clots present, thus preventing morbidity due to fibrothorax and empyema. Tube thoracostomy, which can be in itself the definitive treatment in chest injury, has a 2-30% incidence of retaining clots, requiring further intervention for cleaning (12, 4). The aim of this study is to delineate in a precise way the diagnostic and therapeutic role of videothoracoscopy in thoracic trauma and to evaluate its efficacy.

Patients and Methods

From 1st January 1993 to 30th September 2003 112 traumatized patients underwent a videothoracoscopy, 75 males (67%) and 37 females (33%) with an average age of 55 ± 1 year (range: 16 - 75 years). Trauma origin varied: 60 road accidents (53.6%), 42 accidental falls (37.5%), 7 knife wounds (6.3%) and 3 firearm wounds (2.6%). Clinical patterns were: 76 hemothorax (67.8%), 21 hemopneumothorax (18.7%), 10 suspected diaphragmatic injuries (9%) and 5 pericardium effusions (4.5%). All patients underwent preoperative testing including a general evaluation (hemochrome with leukocyte formula and electrolytes, liver function), blood gas analysis, electrocardiogram, lung radiography, CT of the thorax and other diagnostic procedures that allow visualization of the associated lesions. Patients were hemodynamically stable, conscious and with blood gas analysis compatible with monopulmonary ventilation. Time between trauma and VAT was 18 ± 1 hours.

Videothoracoscopy technique

Selective intubation was performed under general anaesthesia. Cardio-respiratory parameters were carefully monitored. The patients were placed in the standard thoracotomic position, in case thoracotomy became necessary. An 8 mm trocar was positioned in the sixth or seventh intercostal space in the midaxillary line, to provide passage for 0° optical. The pleural cavity along with other organs (chest wall, hemidiaphragm, lung, pericardium) was inspected for damage. Video assisted thoracic surgery required a one or two further trocars, to facilitate dissection and repair of the lesion. Haematic effusion was aspirated and blood clots were removed after breaking up. When no injury was found, we placed a drainage tube 32 Ch through the camera access. Only the diaphragmatic lacerations with a diameter superior to 3 cm were treated by thoracotomy or laparotomy. All patients were extubated in immediate postoperative time.

Statistical analysis

Two analysis were carried out. The first evalua-

tion included the time between trauma and VATS, the morbidity and the length of hospital stay in 21 hemopneumothorax, in which the parenchymal laceration was treated by a stapling device with or without polytetrafluoroethylene (PTFE). Statistical analysis was performed with SPSS (Windows release 6.1) and the statistical significance was estimated by Student t test for unpaired data. Data were expressed as mean \pm standard deviation and 95% Confidence Interval (CI). Difference was considered significant if the p values were less than 0.05 level. The second evaluation included the time between trauma and VATS and the length of hospital stay in the same pathology. All p values less than 0.05 were considered to indicate significance, whereas the correlation coefficient (r) was analyzed using a correlation analysis.

Results

No operative or perioperative deaths were observed. Fifteen patients required a blood transfusion. In suspected diaphragmatic injury patients, videothoracoscopy allowed discovery of 2 lesions in the left side (7 cm and 8 cm) and 2 lesions in the right side (8 cm and 10 cm), treated by thoracotomy in the VIII intercostal space and separate suture stitches. Six VAT resulted negative after careful exploration of the pleural cavity and the procedure ended with thoracostomy tube application. In the patients affected by a firearm wound, VAT revealed: 1) a double laceration of the diaphragm; 2) a 2 cm diaphragmatic lesion; 3) a lung laceration. Treatment required respectively: 1) the positioning of a drainage tube in the thorax and a conversion into laparotomy in order to repair the diaphragm and to explore the abdominal organs more easily; 2) repair of the diaphragm in videothoracoscopy with separate stitches; 3) the carrying out of a wedge-resection of parenchyma in VATS with stapler device. Nine microlesions of the diaphragm (6 in the left side and 3 in the right side), with 2-3cm diameter, due to a knife wound (4 cases) and fractured rib stumps (5 cases) were sutured in VATS with separate stitches. Eleven patients showed wall bleeding following rib fractures; we carried out a coagulation of the pleural surface and insertion of drainage tube. In the remain-

Table 1. VATS procedures in 54 hemothorax patients

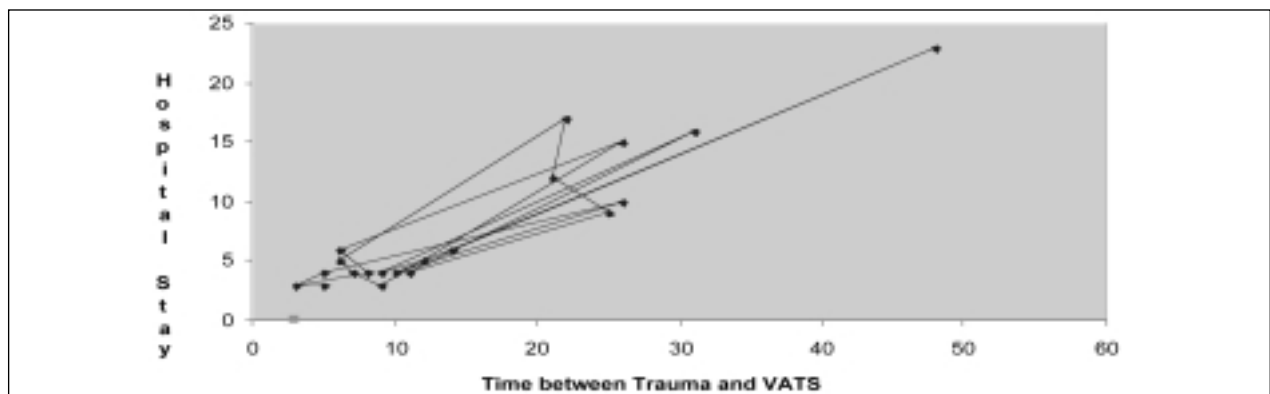
Causes	Number
Intercostal artery lesions	25
Apical adhesions lacerations	19
Diaphragmatic vessel lesions	10

ning 54 hemothorax patients VAT was converted in VATS (Table 1), allowing the lesions repair. Videothoracoscopy exploration in hemopneumothorax suggested diagnosis of parenchymal lacerations owing to a knife wound in 3 patients, a firearm wound in 1 patient, a burst lesion in 7 patients and a rib fracture

in 10 patients. Hemostasis and aerostasis were achieved in VATS by Endo-GIA 30, with or without polytetrafluoroethylene (PTFE) strips to reinforce the stitches. In this group we registered clinical complications only in patients treated videothoroscopically 12 hours after trauma ($r = 0.931$; $p < 0.001$; Table 2). Finally, 5 pericardium effusions linked to pericardium vessel lesions were endoscopically treated by pericardiac fenestration (Figure 1). The mean length of hospital stay in 90 patients (80.3%), treated with VATS, was 4 ± 1 days (range: 3 - 23 days).

Table 2. Correlation between timing of VATS and morbidity and hospitalization in 21 hemopneumothorax patients

Year and sex	Reinforce lung staple lines	Time between trauma and VATS	Morbidity	Hospital stay	P value
41; M	PTFE	3 ± 0.51 hours	/	3 ± 1 days	< 0.04
35; M	PTFE	5 ± 0.34 hours	/	4 ± 2 days	< 0.01
28; M	PTFE	26 ± 0.12 hours	Pneumonia	10 ± 1 days	< 0.002
54; F	/	10 ± 0.47 hours	/	4 ± 1 days	< 0.01
47; M	/	48 ± 0.13 hours	Pulmonary microembolism	23 ± 3 days	< 0.003
23; F	/	14 ± 0.26 hours	Atelectasis	6 ± 2 days	< 0.004
16; F	PTFE	12 ± 0.57 hours	/	5 ± 3 days	< 0.01
53; M	PTFE	9 ± 0.30 hours	/	4 ± 2 days	< 0.02
42; M	/	31 ± 0.19 hours	Pneumonia	16 ± 4 days	< 0.005
53; F	/	11 ± 0.58 hours	/	4 ± 2 days	< 0.01
32; M	PTFE	25 ± 0.35 hours	Pneumonia	9 ± 4 days	< 0.001
30; M	/	21 ± 0.18 hours	Atelectasis	12 ± 1 days	< 0.002
61; M	/	22 ± 0.39 hours	Atelectasis	17 ± 1 days	< 0.003
33; F	/	6 ± 0.10 hours	/	5 ± 1 days	< 0.05
66; M	PTFE	7 ± 0.23 hours	/	4 ± 1 days	< 0.01
39; F	/	9 ± 0.15 hours	/	3 ± 1 days	< 0.001
44; F	/	26 ± 0.41 hours	Pneumonia	15 ± 2 days	< 0.006
71; M	/	6 ± 0.34 hours	/	6 ± 1 days	< 0.004
69; M	/	8 ± 0.53 hours	/	4 ± 1 days	< 0.02
52; M	/	3 ± 0.15 hours	/	3 ± 1 days	< 0.05
41; F	/	5 ± 0.20 hours	/	3 ± 1 days	< 0.03



$r = 0.931$; $p < 0.001$

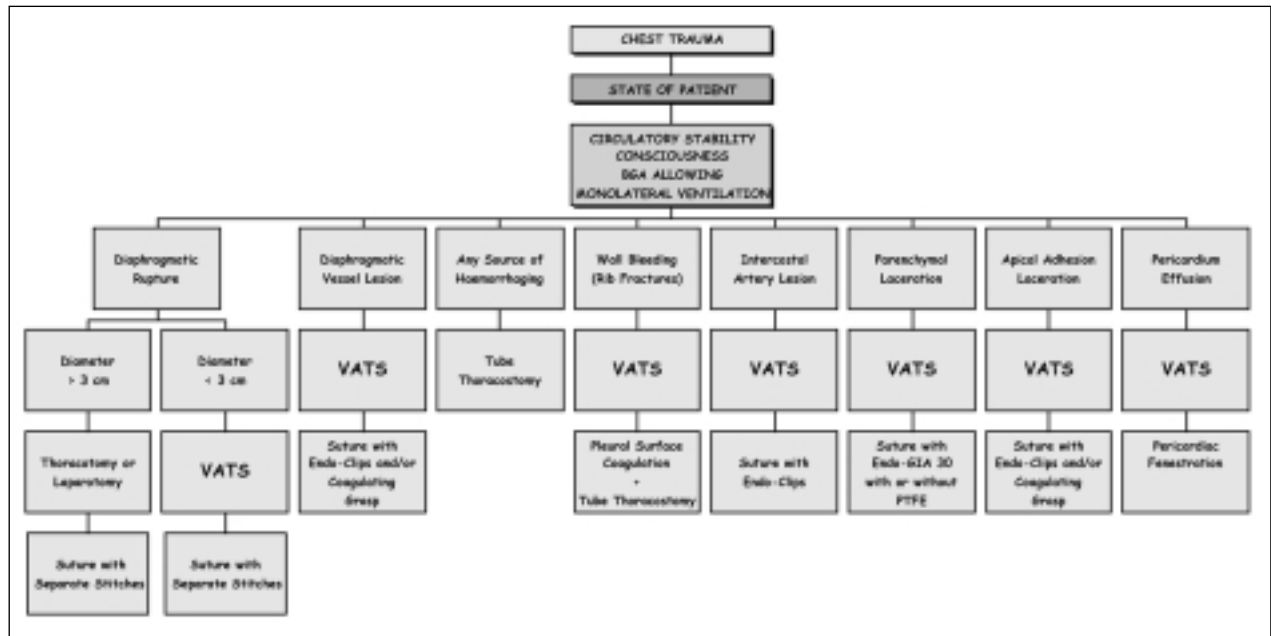


Figure 1. Video Assisted Thoracoscopy Procedure Algorithm for Thoracic Injury (BGA = Blood Gas Analysis)

Discussion

Our study showed that videothoracoscopy permits a rapid diagnosis and a less invasive, safer and easier treatment in chest trauma. In fact, it allows an immediate evaluation of causes of bleeding and associated damage, very good hemorrhaging control with anaemic prevention leading to a better therapeutic solution in the choice of VATS, thoracotomy or laparotomy. Videothoracoscopy led to a swift and complete functions recovery in the patient preventing fibrothorax, empyema or delayed rupture of the diaphragm. The shorter duration of drainage tube, a significant reduction in hospital stay (4 ± 1 days in our study for 400 euros x day) and of hospital costs, among which inexpensive treatment in VATS (466.9 – 854.16; Table 3), are shown in our experience. Eddy et al (6) highlighted empyema in 5% of patients requiring urgent tube thoracostomy, due to incomplete drainage of the pleural space and prolonged tube insertion. Villavicencio et al (16), analysing the thoracoscopy results in trauma, detected a 98% of diagnostic accuracy in diaphragmatic injuries (DI), a total evacuation of hemothorax and empyema in 90% and 86% of cases respectively and chest tube bleeding control in 82.5%.

The improvement of endoscopic materials permitted an exact dissection and exhaustive exploration of the pleural cavity, to which lower postoperative pain and excellent aesthetic auditing may be added; a variety of pathologic situations of the chest, exclusively treated with thoracotomy was managed in VATS (3). This technique can be applied only in conscious, hemodynamically stable patients with a blood gas analysis compatible with monolateral exclusion; clinical and/or radiologic suspicion of cardiac or big blood vessels lesions, following a mediastinal widening superior to 8cm, or a tracheo-bronchial laceration must induce a thoracotomic or sternotomic approach in primary intention. In our study VAT permitted a complete cleaning of the pleural cavity in 91 patients affected by he-

Table 3. Cost of room surgery in case of conversion from VAT in VATS

Materials	Mean Costs
Trocar	125 euros
Endo-GIA 30	129 euros
Recharge of Stapler	89 euros
Propophol 10 mg/ml	23 euros
Silicone Drainage Tube	13.9 euros
PTFE	121.36 euros x 2 pieces
Endo-Clips	180 euros

mothorax, pericardium effusion and suspected diaphragmatic rupture. This method represented the only practice performed in 17 patients (18.6%) without source of haematic loss; the thoracostomy tube was positioned under direct visualization. The percentage of conversion of VAT into VATS was 75.8% (69 patients), into thoracotomy 4.4% (4 patients) and into laparotomy 1.1% (1 patient). Abolhoda et al (1), in a series of 16 patients, registered 4 conversions in thoracotomy (25%) due to inefficient monolateral ventilation or an important inflammatory pleural reaction; 12 patients (75%) were successfully treated with videothoracoscopy. Although the Authors believe that evacuation of blood clots in hemothorax is easy until 7 post-injury days, we believe that the ideal timing for videothoracoscopy is within 12 hours following trauma (18 ± 1 hours altogether in our experience) in order to facilitate thorax inspection and injury treatment thus avoiding formation of inveterate lesions and postoperative morbidity. In fact, in 21 hemopneumothorax we observed 4 pneumonias, 3 atelectasis and 1 pulmonary microembolism in patients who underwent VATS at 12 hours from trauma; these complications were positively solved in all cases but prolonged hospitalization. Meyer et al (11) analysed 39 hemothorax patients treated with 36 F tube thoracostomy in primary intention, who showed persistent hemothorax or hemopneumothorax within 72 hours from the initial drainage placement. Subsequently, these patients underwent a second tube insertion or VATS. In a VATS group the Authors observed a reduction in duration of drainage tube (2.53 ± 1.36 vs 4.50 ± 2.83 days), in hospital stay (3.60 ± 1.64 vs 7.21 ± 5.30) and in hospital costs ($\$ 7,689 \pm 3,278$ vs $\$ 13,273 \pm 8,158$). Liu et al (9), in 56 hemothorax or posthemothorax complication patients with penetrating (23 cases) and blunt (33 cases) injuries, applied VATS successfully in 50 patients (89.2%) without morbidity; 6 patients (10.8%) affected by cardiovascular lesions (4 cases) and chest wall lacerations (2 cases) were not treated with VATS. These studies clarified that early inspection of the pleural cavity in videothoracoscopy and direct treatment of injuries reduced short-term and long-term complications of chest trauma. Heniford et al (8) had used VATS in 19 patients (76%) in order to evacuate retained hemothorax and thoracotomy in 4 patients

(16%); 2 patients (8%) needed further strategy to drain collection. The unsuccess of VATS was linked to the time between injury and intervention (14.5 days; successful 4.5 days) and the nature of collection (hemothorax vs empyema).

The use of thoracoscopy in diagnosis and treatment of patients with penetrating chest trauma has been described by Branco (2) since 1946. Oakes et al (13) highlighted that thoracoscopy in penetrating chest injury reduces the need for thoracotomy. Uribe et al (15), evaluating by videothoracoscopy 28 patients with thoraco-abdominal penetrating trauma, thought that this technique provides excellent identification of diaphragmatic injury and evacuation of blood clots from the pleural cavity. Martinez et al (10) referred to VATS 52 penetrating thoraco-abdominal trauma patients without indications for urgent surgery; 40 (76.9%) of them were clinically asymptomatic. The Authors diagnosed 35 diaphragmatic injuries (67.3%), easily repaired by thoracoscopy. The diagnostic accuracy of chest radiography and computed tomography in diaphragmatic injuries is inferior to 50% (14). We believe that, in selected penetrating wound patients, the use of videothoracoscopy can represent a main legal role besides precisely defining the trajectory of bullet or knife wounds. Freeman et al (7), in a retrospective review of 171 patients undergoing VATS after penetrating chest trauma, established five independent predictors of diaphragmatic injuries (abnormal chest radiograph, entrance wound inferior to nipple line, intraabdominal injuries, right-sided entrance wound and high-velocity mechanism). They advised videothoracoscopy only in patients in whom two or more independent predictors of DI were identified.

We concluded that early videothoracoscopy is safe and the fastest method for diagnosis and surgical management in chest trauma. This technique makes the use of primary intention drainage tube obsolete in stable patients with hemothorax and hemopneumothorax. A diaphragmatic injury with a diameter superior to 3cm is the only therapeutic limit.

References

1. Abolhoda A, Livingston DH, Donahoo JS, Allen K. Diagnostic and therapeutic video assisted thoracic surgery (VATS) following chest trauma. *Eur J Cardio-thorac Surg* 1997; 12: 356.
2. Branco JMC. Thoracoscopy as a method of exploration in penetrating injuries of the chest. *Dis Chest* 1946; 12: 330.
3. Carrillo EH, Richardson JD. Thoracoscopy in the management of hemothorax and retained blood after trauma. *Curr Opin Pulm Med* 1998; 4: 243.
4. Coselli JS, Mattox KL, Beall AC Jr. Reevaluation of early evacuation of clotted hemothorax. *Am J Surg* 1984; 148: 786.
5. Crisci R. Videothoracoscopy in chest trauma. *Endosurgery* 1998; 6: 93.
6. Eddy AC, Luna GK, Copass M. Empyema thoracis in patients undergoing emergent closed tube thoracostomy for thoracic trauma. *Am J Surg* 1989; 157: 494.
7. Freeman RK, Al-Dossari G, Hutcheson KA, et al. Indications for using video-assisted thoracoscopic surgery to diagnose diaphragmatic injuries after penetrating chest trauma. *Ann Thorac Surg* 2001; 72: 342.
8. Heniford BT, Carrillo EH, Spain DA, Sosa JL, Fulton RL, Richardson JD. The role of video-assisted thoracoscopy in the management of retained thoracic collections after trauma. *Ann Thorac Surg* 1997; 63: 940.
9. Liu DW, Liu HP, Lin PJ, Chang CH. Video-assisted thoracic surgery in treatment of chest trauma. *J trauma* 1997; 42: 670.
10. Martinez M, Briz JE, Carrillo EH. Video-thoracoscopy expedites the diagnosis and treatment of penetrating diaphragmatic injuries. *Surg Endosc* 2001; 15: 28.
11. Meyer DM, Jessen ME, Wait MA, Estrera AS. Early evacuation of traumatic retained hemothoraces using thoracoscopy: a prospective, randomized trial. *Ann Thorac Surg* 1997; 64: 1396.
12. Milfeld DJ, Mattox KL, Beall AC Jr. Early evacuation of clotted hemothorax. *Am J Surg* 1978; 136: 686.
13. Oakes DD, Sherck JP, Brodsky JB, Mark JBD. Therapeutic thoracoscopy. *J Thorac Cardiovasc Surg* 1984; 87: 269.
14. Toombs BD, Sandler CM, Lester RG. Computer tomography of chest trauma. *Radiology* 1981; 150: 733.
15. Uribe RA, Pachon CE, Frame SB, Enderson BL, Escobar F, Garcia GA. A prospective evaluation of thoracoscopy for the diagnosis of penetrating thoracoabdominal trauma. *J Trauma* 1994; 37: 650.
16. Villavicencio RT, Aucar JA, Wall MJ Jr. Analysis of thoracoscopy in trauma. *Surg Endosc* 1999; 13: 3.

Received: 23 January 2004

Accepted in original form: 13 December 2004

Correspondence: Dr. Duilio Divisi

Circonvallazione Ragusa 39

64100 Teramo (Italy)

Tel: +39 0861 429482

Fax +39 861 211626

E-mail address: duilio.divisi@virgilio.it