

# Totally laparoscopic esophago-gastrectomy

*Renato Costi<sup>1,2</sup>, Jacques Himpens<sup>1</sup>, Basile Essola<sup>1</sup>, Leopoldo Sarl<sup>2</sup>, Vincenzo Viol<sup>2</sup>, Luigi Roncoron<sup>2</sup>, Guy Bernard Cadière<sup>1</sup>*

<sup>1</sup>Clinique de Chirurgie Digestive, CHU Saint-Pierre, Université Libre de Bruxelles, Belgique, and <sup>2</sup>Dipartimento di Scienze Chirurgiche, Università di Parma, Italia

**Abstract.** The recent progress of surgical endoscopy has allowed to perform minimally invasive esophagectomy both by a combined laparoscopic/thoracoscopic and a totally laparoscopic transhiatal approach. Up to now, all these techniques imply a thoracic (or thoracoscopic) and/or cervical access to perform the esophago-gastric anastomosis. In the presented case, a 44-year-old white male patient affected by adenocarcinoma of the cardia (Siewert type 2) underwent a distal esophagectomy entirely accomplished by laparoscopy (including the realization of a mechanical intrathoracic esophagogastrostomy), without the need of any thoracic (nor thoracoscopic) nor cervical access. Duration of surgery was 407 minutes. Postoperative course was uneventful and the patient was discharged on day 7. In selected cases, a totally laparoscopic esophago-gastrectomy without thoracic nor cervical access, may improve the patient's outcome

**Key words:** Transhiatal esophagectomy, laparoscopy, mechanical esophagogastrostomy, cardia, adenocarcinoma

## Introduction

A wide variety of minimally invasive esophago-gastrectomy techniques have been proposed. Some authors have suggested a totally laparoscopic transhiatal approach with cervical anastomosis (1, 2), whereas others prefer a combined approach by laparoscopy and thoracoscopy with cervical anastomosis (3). Very recently, few reports (4, 5) describe a combined laparoscopic/thoracoscopic approach with the thoracoscopic realization of the esophagogastrostomy, so avoiding the need of a cervical incision.

Up to now, a thoracic (or thoracoscopic) and/or cervical access has been considered necessary for an effective lymphadenectomy and/or to perform the esophago-gastric anastomosis.

Here we present a patient's case who underwent a distal esophagectomy for adenocarcinoma of the cardia (Siewert type 2), entirely carried out by laparo-

scopy, without any thoracic, thoracoscopic nor cervical access.

## Case report

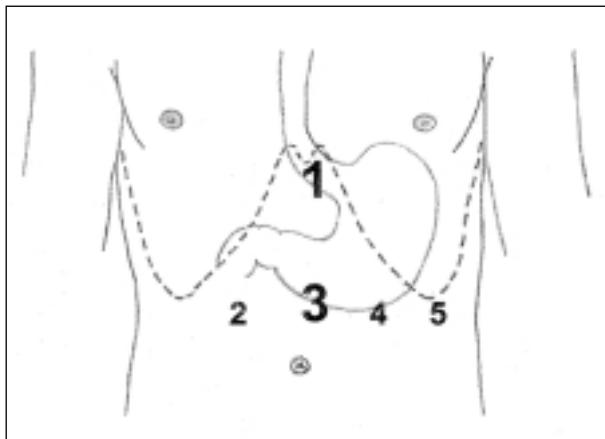
In September 2000, an otherwise asymptomatic 44-year-old white man had complained of dysphagia and weight loss (12 kgs). Esophagogastrroduodenoscopy (EGDS) and endoscopic ultrasounds showed an oval-shaped, 6X2 mm T2N0 lesion of the cardia (Siewert type 2). CT scan showed no thoracic nor abdominal metastases. The patient was referred for surgery at the Clinique de Chirurgie Digestive, Saint-Pierre University Hospital (Bruxelles).

The patient was placed in a 25 degrees anti-Trendelenburg position; the operating surgeon (GBC) was situated between the legs, the assistant surgeon (RC) and the instrument nurse were on the left side of

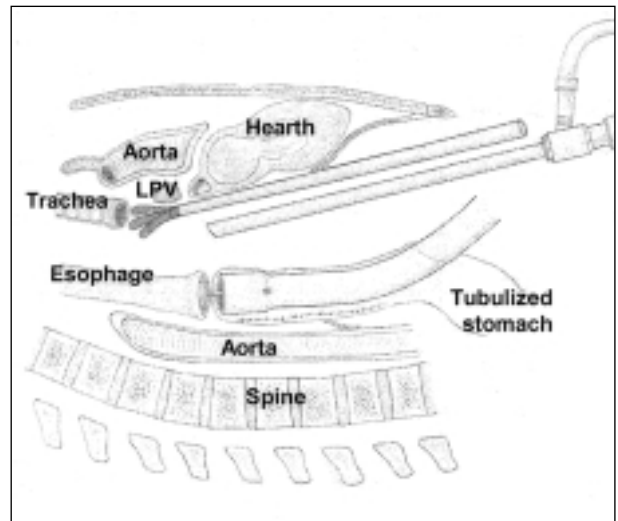
the patient, and the camera-holding surgeon (BE) on the right side. A 14 mmHg pneumoperitoneum was induced through a Veress' needle. Five trocars (three 5 mm and two 10 mm) were introduced (Figure 1). A 30-degree optics was used.

After retraction of the left lobe of the liver with a three-digits 10 mm retractor (ENDO RETRACT®, United States Surgical Corp., Norwalk, CT, USA), the right diaphragmatic crura were dissected. The gastro-hepatic ligament was interrupted to expose the left gastric vessels. The greater curvature was mobilized from distally to proximally, preserving the right gastric and right gastro-epiploic arteries. The Kocher manoeuvre was performed to mobilize the stomach. Lymphadenectomy of the celiac trunk was completed and the pancreatic capsula was opened from left to right until reaching the hepatic pedicle, which was dissected. The splenic artery was dissected, whereas left gastro-epiploic vessels were clipped and interrupted. Gastric tubulization was realized by means of an endoscopic linear stapler (ENDO GIA®, U.S.S.C.).

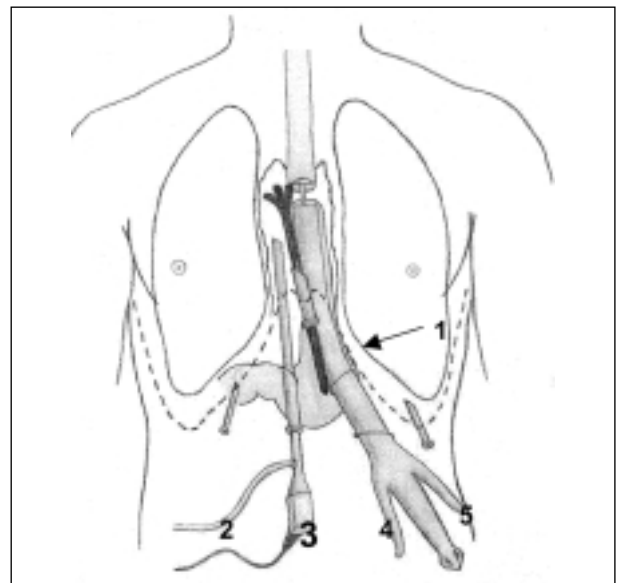
The diaphragmatic crus were opened and cut by harmonic scalpel (ULTRACISION®, Ethicon Endosurgery, Cincinnati, OH, USA). The limits of mediastinal dissection were: 1. anteriorly, the pericardium and the left pulmonary vein, 2. posteriorly, the aorta (Figure 2) and 3. on the sides, the left and right parietal pleuras (Figure 3). The three-digits retractor was placed on the heart and moved proximally. The mediastinum was proximally dissected according to on-



**Figure 1.** Trocars' position. Port-sites 1 and 3 are 10 mm; port-sites 2, 4 and 5 are 5 mm



**Figure 2.** Mediastinal dissection and laparoscopic esophago-gastric anastomosis, lateral view of the thorax.  
*LVP: Left Pulmonary Vein*



**Figure 3.** Mediastinal dissection and laparoscopic esophago-gastric anastomosis, anterior view (port-site 4 is enlarged to allow the extraction of the specimen and the introduction of mechanical stapler)

cological exigencies, over the left pulmonary vein superior margin. The esophagus was interrupted and the specimen was inserted in a specimen bag.

In order to perform the gastro-esophageal anastomosis, the anvil of the stapler (PREMIUM PLUS

CEEA 25 w/ Tilt-Top®, U.S.S.C.) was inserted in the esophageal stump, after having entered the abdomen through a port-site (port-site 4 in figure 1). The mechanical stapler was introduced in the abdomen by enlarging the same trocar-site and inserted in the previously tubulized stomach by an accessory hole. The stapler and the anvil were connected and the anastomosis was performed under the 30-degrees optics' view. Some stitches were added by intracorporeal suturing device (ENDO STITCH®, U.S.S.C.). The specimen bag was extracted through one of the trocar sites (port-site 4).

The duration of surgery was 407 minutes. The intraoperative blood loss was 400 cc. The patient was extubated in the operating room and transferred to the intensive care unit and morphine was administered two days postoperatively. The patient was transferred to the surgical floor on day 2. Postoperative course was uneventful. The patient had bowel movement on day 4 and was discharged on day 7 postoperatively. Pathological examination of the specimen showed a low differentiated adenocarcinoma of the cardia infiltrating the serosa, with no metastases in 13 lymph nodes (pT3N0). Forty-two months after surgery, the patient is doing well, with no signs of local recurrence or distant metastases.

## Discussion

The open transhiatal esophagectomy (6) consists of a laparotomy for the dissection and mobilization of the stomach and the dissection of the esophagus, and a left cervicotomy to perform the esophago-gastric anastomosis. During the last decades, the transhiatal esophagectomy has challenged the role of the traditional Ivor Lewis procedure (7), having been reported the same long-term results, with significantly lower mortality and morbidity rates (6).

During the nineties, minimally invasive versions of both transhiatal (1, 2) and Ivor Lewis (3) esophagectomy have been proposed. The technique we and other authors (1, 2) usually perform for the adenocarcinoma of the cardia (Siewert type 2) is a laparoscopic transhiatal esophagogastrectomy (distal esophagectomy/proximal gastrectomy) with a cervical access to

allow the delivery of the specimen and the creation of the esophagogastrostomy.

In the present case, we have been able to accomplish the whole procedure by laparoscopy, and to avoid the otherwise necessary cervical incision. During the abdominal stage, laparoscopy has allowed the mobilization, division and tubulization of the stomach and a wide lymphadenectomy. During the thoracic stage, laparoscopy has allowed a good visualization of the mediastinum, the dissection and resection of large tumor-free esophageal margins, a two-fields mediastinal lymphadenectomy and the realization of the intrathoracic esophagectogastrostomy by mechanical stapling.

From a technical point of view, owing to the narrowness and the depth of the operating field, the use of 30-degrees optics, 10 mm. three-digits retractor and harmonic scalpel has to be considered mandatory. Even though the esophagogastrostomy has proved to be reliable, it still represents the main limitation of this technique. The difficulty is not derived from the surgical act, easily accomplished by means of the mechanical stapler, but from the inadequate length of surgical instruments at such a distance from port-sites.

Although a single operation performed by a skilled laparoscopic surgeon obviously does not allow any generalization, the presented case shows that this technique is technically demanding but feasible and seems to maximize the advantages of minimally invasive approach, as witnessed by the fast recovery of bowel movement and the shortened hospital stay.

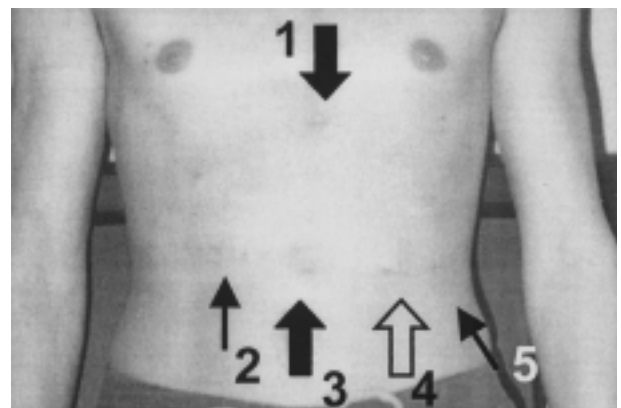


Figure 4. Abdominal scars three months after totally laparoscopic distal esophagogastrectomy. There are no cervical nor thoracic scars

Although randomized prospective studies on larger series of patients are needed to validate this technique with respect to long term surgical and oncological results, the morbidity of this totally laparoscopic technique should be reduced by avoiding complications eventually associated with cervical incision (1-3, 6, 7) and thoracic (7) (or thoracoscopic (4, 5)) access. Finally, since no cervical nor thoracic incision are performed, cosmetic result is excellent (Figure 4).

## References

1. de Paula AL, Hashiba K, Ferreira EA, de Paula RA, Grecco E. Laparoscopic transhiatal esophagectomy with esophago-gastroplasty. *Surg Laparosc Endosc* 1995; 5: 1-5.
2. Swanstrom LL, Hansen P. Laparoscopic total esophagectomy. *Arch Surg* 1997; 132: 943-7.
3. Luketich JD, Schauer PR, Christie NA, et al. Minimally invasive esophagectomy. *Ann Thorac Surg* 2000; 70: 906-11.
4. Nguyen NT, Follette DM, Lemoine PH, Roberts PF, Goodnight JE Jr. Minimally invasive Ivor Lewis esophagectomy. *Ann Thorac Surg* 2001; 72: 593-6.
5. Watson DI, Davies N, Jamieson GG. Totally endoscopic Ivor Lewis esophagectomy. *Surg Endosc* 1999; 13: 293-7.
6. Orringer MB, Marshall B, Iannettoni MD. Transhiatal esophagectomy: clinical experience and refinements. *Ann Surg* 1999; 230: 392-400.
7. Lewis I. The surgical treatment of carcinoma of the esophagus with special reference to a new operation for growths of the middle third. *Br J Surg* 1946; 34: 18-31.

---

Received: 5 March 2004

Accepted in modified version: 15 December 2004

Correspondence: Renato Costi, M.D., Ph.D.

Dipartimento di Scienze Chirurgiche

Università degli Studi di Parma

Via Gramsci 14,

43100 Parma, Italy

Tel. +39.335.8234285

Fax: +39.0521.940125

E-mail: renato.costi@unipr.it