

“Late” regressions of metastases from renal cancer after a period of disease progression continuing the same intermittent low dose immunotherapy regimen

Roberto Giacosa, Rosaria Santi, Augusto Vaglio, Laura Pavone, Francesco Ferrozzi¹, Rodolfo Passalacqua², Carlo Buzio

Department of Clinical Medicine, Nephrology and Health Science, University of Parma, Parma, Italy

¹ Radiological Institute “Figlie di S. Camillo”, Cremona, Italy

² Division of Medical Oncology, “Azienda Istituti Ospitalieri”, Cremona, Italy

Abstract. We here describe two patients with metastatic renal cell cancer (mRCC) treated with immunotherapy in whom the metastases completely regressed after a period of progressive disease. The treatment schedule was based on repeated cycles of low-dose recombinant interleukin-2 and recombinant interferon- α , and was never changed during the course of the disease. The first patient received immunotherapy because of multiple bilateral lung metastases. Progressive disease, with mediastinal lymph node involvement and an increased number of lung metastases, was observed after 30 months of regularly repeated therapy; complete regression was achieved after 60 months of immunotherapy (after 16 immunotherapy cycles). The second patient began immunotherapy because of three small lung metastases. Disease progression was observed after three cycles, but complete regression was obtained about 16 months after the start of immunotherapy (after 5 immunotherapy cycles). Long-term low-dose immunotherapy may bring about an effective anti-tumour response even late in the course of the disease and after an initial disease progression.

Key words: Tumour regression, metastatic renal cell cancer, interleukin-2, interferon- α , immunotherapy

Introduction

Bumpus (1) first described the disappearance of a pulmonary metastasis in a 59-year-old man with metastatic renal cell cancer (mRCC) in 1928 and, since then, about 70-80 cases have been reported in the English literature (2). Renal cell cancer (RCC) is associated with the highest incidence of regression of metastases (1-3%) (3, 4), followed by lymphoma/leukaemias, neuroblastoma, carcinoma of the breast and melanoma (3). In the majority of the published cases, the regressions of metastases from RCC have been related

to the previous nephrectomy and were not preceded by an increase in volume.

These regressions are usually referred to as “spontaneous”, defined by Everson and Cole (5) as the “partial or complete disappearance of a malignant tumour in the absence of treatment or in the presence of the therapy which is considered inadequate”.

Medical therapy for mRCC patients is usually based on the administration of recombinant interleukin-2 (rIL-2) and/or recombinant interferon- α (rIFN α). We have shown (6) and recently confirmed (7) the effectiveness of an original immunotherapeu-

tic schedule based on the long-term administration of repeated cycles of intermittent low-dose rIL-2 and rIFN α . This protocol was associated with an overall clinical response of about 15% and a survival probability of 47% at 36 months.

We here describe two cases, out of a cohort of fifty mRCC patients with multiple metastases, who were treated with the above mentioned intermittent low-dose rIL-2 and rIFN α at our institution. Despite they initially showed progressive disease, they later on achieved complete disease remission, continuing the same medical treatment despite progression.

Case reports

Case 1

A 57-year-old man was diagnosed as having RCC and therefore underwent right nephrectomy in January 1989; histology showed a clear cell RCC within the renal cortex, without any capsular or hilar vessel invasion. The TNM clinical stage was T2N0M0 (according to the TNM staging system (8)), and the histopathological grade G3 (according to Fuhrman's classification (9)).

He did not receive any further treatment and, 30 months later, in July 1991, a chest X-ray revealed multiple bilateral pulmonary nodules consistent with metastatic cancer, thus the patient was referred to our centre. A chest computer tomography (CT) scan, performed in January 1992, confirmed the presence of four lung metastases: two in the right apex and middle lobe (respectively 0.5 x 0.5 and 0.9 x 0.8 cm), and two in the left upper lobe (1 x 0.9 and 2 x 1.2 cm); right hilar lymph node enlargement was also observed (1.8 cm) (Fig. 1a). No other metastatic sites were apparent. Low-dose rIL-2 and rIFN α -based immunotherapy was started in January 1992. rIL-2 was administered subcutaneously at a dosage of 1×10^6 IU/m² every 12 hours on days 1 and 2 and daily on days 3-5 of each week. rIFN α was administered intramuscularly at a dosage of 1.8×10^6 IU/m² daily on days 3 and 5 of each week. Each cycle consisted of four consecutive weeks and it was repeated indefinitely at 4-month intervals.

Eight cycles were administered over the following 30 months, showing disease stability.

In June 1994, an initial disease progression was demonstrated by the *de novo* appearance of two lung metastases (in the right upper lobe and in the left lower lobe) and the gross enlargement of the right hilar mass (4 cm) (Fig.1b). In accordance with our protocol, he continued the treatment without any change in doses and schedules, despite the progression of the disease.

In January 1995, as from the 36th month of immunotherapy, the metastatic bulk began to decrease slowly but continuously. Complete re-staging after 60 months of regular immunotherapy (16 cycles) documented the disappearance of all the radiological signs of metastatic lesions, including those in the right hilum (Figs. 1c, 1c') and pulmonary parenchyma. This "late" complete response persisted for eight months before the recurrence of disease due to the presence of a single bone metastasis.

The patient died in September 1997 of tumour-related causes after having undergone 23 cycles of immunotherapy. Survival calculated from the start of treatment was 69 months.

Case 2

A 55-year-old man underwent radical left nephrectomy because of RCC in March 1996. Pathological examination of the surgical specimen revealed a well-differentiated (G1) 15-cm clear cell RCC, without any capsular or hilar vessel infiltration; all of the nine examined lymph nodes were disease free. A CT scan performed at the time of nephrectomy revealed three small lung metastases (< 10 mm), located peripherally, two in the right and one in the left lung, although a chest X-ray had showed no evidence of metastases (Fig. 2a). The TNM clinical stage was T2N0M1.

One month after nephrectomy, the patient came under our observation and began immunotherapy, following the same schedule described in Case 1.

A chest X-ray was performed in April 1997, after three cycles (Fig. 2b) and it revealed the appearance of two pulmonary nodules localized in the upper right lobe (3.9 x 3.6 cm) and pericardially in the lower left lobe (1.8 x 1.1 cm), thus indicating disease progression.

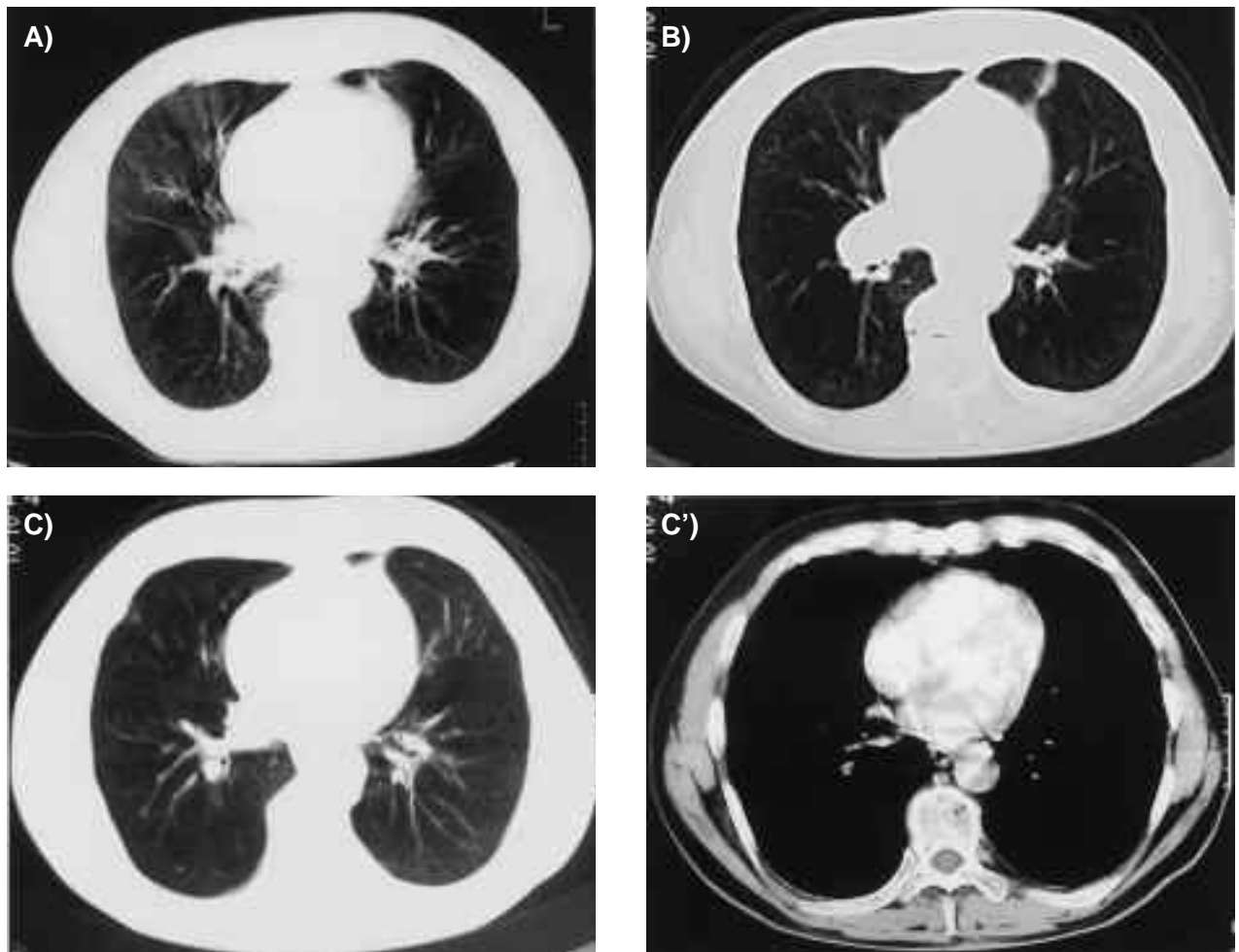


Figure 1. A. CT scan before treatment showing right hilar adenopathy (1.8 cm), as well as diffuse emphysema and pulmonary fibrosis. B. Progressive disease: CT scan performed 1 cm cranially to 'A' 30 months (eight cycles) after the beginning of immunotherapy showing the increased size of the hilar lesion (4 cm). Parenchymal consolidation with pleural attachment can also be seen in the lingula. C, C'. "Late" complete remission 60 months (16 cycles) after the beginning of immunotherapy: CT scans with lung (c) and mediastinum (c') windows showing the resolution of the hilar lesion and a residual fibrous scar.

Sixteen months after nephrectomy (and after five cycles of immunotherapy), a chest X-ray in June 1997 showed that the metastatic nodules had completely disappeared (Fig. 2c) and a CT scan performed in July 1997 confirmed the "late" complete response.

The response persisted for 18 months (during which five further cycles of immunotherapy were administered), before the disease resumed its progressive course in February 1999 with the appearance of multiple mediastinal adenopathies.

The patient died in May 2003 from cardiogenic shock; at autopsy a large right atrial mass was found, which caused a complete obstruction to right ventri-

cular filling; histology showed a large metastasis of clear cell carcinoma. He underwent a total of 22 cycles of immunotherapy. Survival calculated from the start of treatment was 85 months.

Discussion

There have been anecdotal reports of the regression of metastases in the absence of nephrectomy (10, 11), but most spontaneous regressions are temporally related to the surgical treatment of the primary tumour (2, 3); some have also been associated with pri-

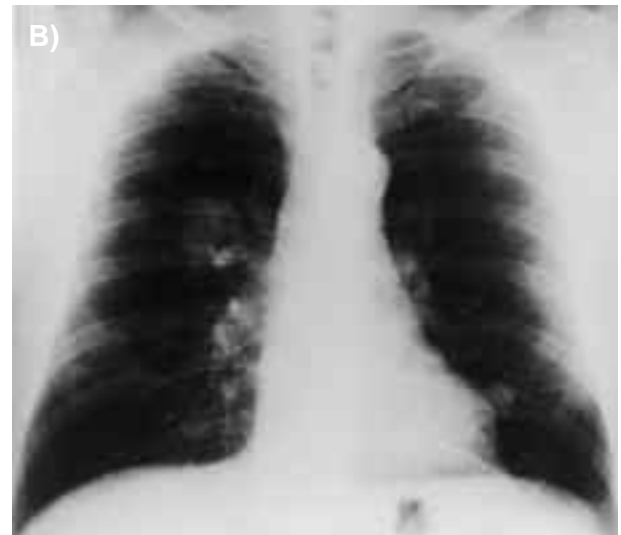
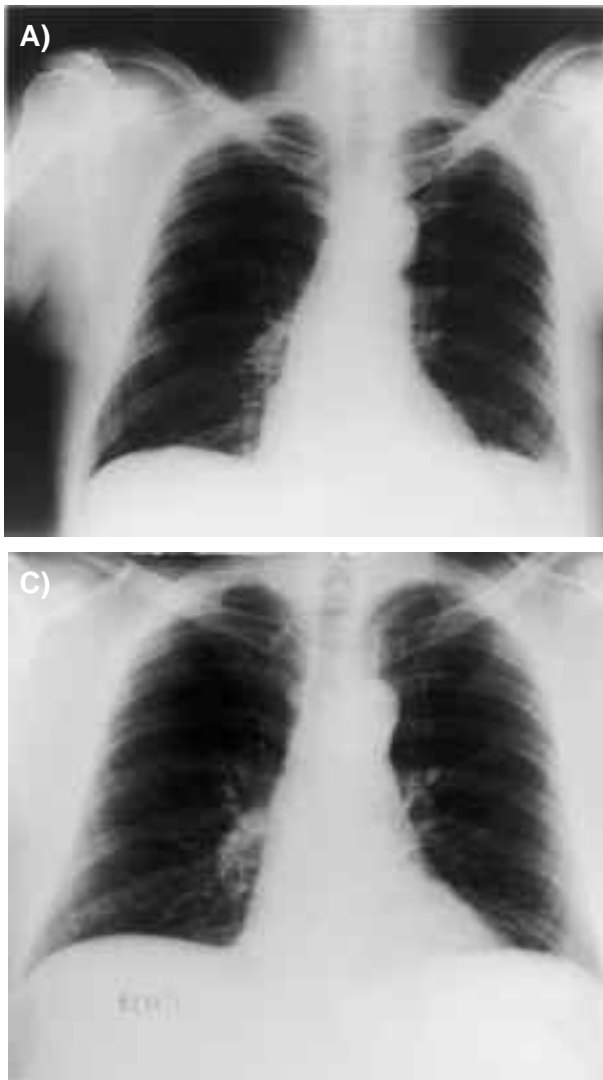


Figure 2. A. Chest X-ray at the time of nephrectomy: no lung or pleural metastases are visible (although a CT scan performed at the same time showed three small parenchymal metastases). B. Progressive disease: X-ray taken 11 months after the beginning of immunotherapy (after three cycles) showing two bilateral nodular opacities, (3.9 x 3.6 and 1.8 x 1.1 cm) localized pericardially in the upper right and lower left lobe. C. “Late” complete remission: X-ray taken 16 months after the beginning of immunotherapy (after five cycles) demonstrating the disappearance of the lung metastases; the findings were confirmed by CT.

mary tumour irradiation (12) or embolization (13). One of the possible mechanisms underlying the control of residual disease in “spontaneous” regressions is that the removal of tumour bulk enables or stimulates the body’s immune system, thus allowing host immune defences to overcome the metastases (2).

The complete responses of our two patients, out of a cohort of fifty mRCC cases (4%), cannot be directly attributed to the previous nephrectomy because of the radiologically documented disease progression after surgery, so these were possibly due to the effect of the immunotherapy.

We use the term “late” regression to indicate the disappearance of the metastases from RCC after a pe-

riod of proved disease progression. This condition is clearly different from the “spontaneous” regressions that are temporally related to previous nephrectomy without any evidence of intermediate disease progression.

One of the distinguishing features of our therapeutic regimen is the low dose of both rIL-2 and rIFN α , which are respectively about 5-8 and 3-8 times lower than those used in other low-dose treatments (14-16). Furthermore, in accordance with medical treatment guidelines in metastatic cancer, the immunotherapy cycles in all the previous trials were repeated only a few times and only in patients responding or stable. Our two patients received repeated

treatment cycles over a long period despite the initial lack of response demonstrated by the progression of the disease.

Our treatment approach was based on the assumption that low-dose rIL-2 has anti-tumour effects linked to the selective expansion of natural killer (NK) cells and antigen-stimulated T lymphocytes (17, 18), and that NK subsets continue to expand without any signs of a plateau effect during long-term immunotherapy (17). Furthermore, reiterated immunotherapy given on a regular basis may boost immune responsiveness, thus overcoming tumour-induced energy (18) and/or inducing tumour dormancy (19).

In conclusion, the "late" regressions observed in our two patients show that immunotherapy may bring about an effective anti-tumour response even late in the course of the disease; in addition, these observations raise doubts as to whether the concept that anti-tumour therapy should be continued only in responsive or stable patients, is applicable in the case of immunotherapy.

References

1. Bumpus HC. The apparent disappearance of pulmonary metastasis in a case of hypernephroma following nephrectomy. *J Urol* 1928; 20: 185-91.
2. Fairlamb DJ. Spontaneous regression of metastases of renal cancer: a report of two cases including the first recorded regression following irradiation of a dominant metastasis and review of the world literature. *Cancer* 1981; 47: 2102-6.
3. Snow RM, Schellhammer PF. Spontaneous regression of metastatic renal cell carcinoma. *Urology* 1982; 20: 177-81.
4. Young RC. Metastatic renal-cell carcinoma: what causes occasional dramatic regressions? *N Engl J Med* 1998; 338: 1305-6.
5. Everson TC, Cole WH. Spontaneous regression of cancer. WB Saunders Co.: Philadelphia, 1966, 11-87.
6. Buzio C, et al. Effectiveness of very low doses of immunotherapy in advanced renal cell cancer. *Br J Cancer* 1997; 76: 541-4.
7. Buzio C, et al. Long-term immunotherapy with low-dose interleukin-2 and interferon-alpha in advanced renal cell cancer. *Cancer* 2001; 92: 2286-96.
8. TNM classification of malignant tumours. Fifth edition. Sobin LH and Wittekind, Ch, eds. Wiley-Liss, New York, 1997, 198-200.
9. Fuhrman SA, Lasky LC, Limas C. Prognostic significance of morphologic parameters in renal cell carcinoma. *Am J Surg Pathol* 1982; 6: 655-63.
10. Ljunggren E, Holm S, Karth B, Pompeius R. Some aspects of renal tumours with special reference to spontaneous regression. *J Urol* 1959; 82: 553-7.
11. Robinson CE. Spontaneous regression in renal carcinoma. *Can Med Assoc J* 1969; 100: 297-300.
12. MacManus MP, Harte RJ, Stranex S. Spontaneous regression of metastatic renal cell carcinoma following palliative irradiation of the primary tumour. *Ir J Med Sci* 1994; 163: 461-3.
13. Mohr SJ, Whitesel JA. Spontaneous regression of renal cell carcinoma metastases after preoperative embolization of primary tumor and subsequent nephrectomy. *Urology* 1979; 14: 5-8.
14. Atzpodien J, Korfer A, Franks CR, Poliwoda H, Kirchner H. Home therapy with recombinant interleukin-2 and interferon alpha-2b in advanced human malignancies. *Lancet* 1990; 335: 1509-12.
15. Vlasveld LT, et al. A phase I study of prolonged continuous infusion of low dose recombinant interleukin-2 in melanoma and renal cell cancer. Part I: Clinical aspects. *Br J Cancer* 1992; 65: 744-50.
16. Yang JC, et al. Randomized comparison of high dose and low dose intravenous interleukin-2 for the therapy of metastatic renal cell carcinoma: an interim report. *J Clin Oncol* 1994; 12: 1572-76.
17. Vlasveld LT, et al. A Phase I study of prolonged continuous infusion of low dose recombinant interleukin-2 in melanoma and renal cell cancer. Part II: Immunological aspects. *Br J Cancer* 1993; 68: 559-67.
18. Caligiuri MA. Low-dose recombinant interleukin-2 therapy: rationale and potential clinical applications. *Semin Oncol* 1993; 20: 3-10.
19. Uhr JV, Scheuermann RH, Street NE, Vitetta ES. Cancer dormancy: opportunities for new therapeutic approaches. *Nat Med* 1997; 3: 505-9.

Received: 11 November 2003

Accepted in revised form: 18 June 2004

Correspondence: Prof. Carlo Buzio,

Dipartimento di Clinica Medica,

Nefrologia e Scienze della Prevenzione,

Via A. Gramsci 14,

43100 Parma, Italy

Tel: +39 0521 702345

Fax: +39 0521 292627

E-mail: carlo.buzio@unipr.it