

Bladder carcinosarcoma: a case observation

Umberto Maestroni, Alessandro Giollo, Antonio Barbieri, Nicola Azzolini, Giovanni Fellegara, Elisabetta Froio*, Massimo Melissari*, Pietro Cortellini*

Azienda Ospedaliera Universitaria di Parma. Unità Operativa di Urologia, Parma, Italy

* Istituto di Anatomia Patologica, Università di Parma, Parma, Italy

Abstract. Carcinosarcoma of the bladder is a very unusual neoplasm that arises more frequently in males with a greater incidence in the seventh decade of life. There are no pathognomonic clinical findings or symptoms to address its presence. Symptoms, as for other bladder cancers, are fundamentally represented by haematuria and dysuria. It has a very aggressive clinical behaviour and it is histologically characterized by a malignant epithelial component associated with a sarcoma-like (sarcomatoid) component variably represented.

Key words: bladder, carcinosarcoma

Clinical case

S.A. male 75 years old, came to our observation for macro-haematuria. Abdominal ultrasound showed a huge mass on the posterior wall of the bladder. At cystoscopy a vegetant, scissile and nodular neoplasia was observed. Histologic examination classified the tumour as "carcinosarcoma". Abdominal, pelvic and thoracic CT scans excluded extension outside the bladder or nodal disease. Bone scan was negative for skeletal localizations. The patient underwent radical cistoprostatovesiculectomy with ileal conduit. Surgical specimen showed a bulky polypoid cancer of 10 x 5 x 3 cm arising from the posterior and right lateral walls of the bladder, occupying up to 75% of the visceral lumen (photo 1). On the cutting surface, solid zones alternated to hard-elastic gelatinous greyish lines in a necrotic-haemorrhagic context. The histological diagnosis was "carcinosarcoma extending to submucosal layer with polypoid endoluminal development. No lymph-nodal involvement was observed (pT1 N0 M0)". No problems occurred up to discharge. After 6 months of close follow-up, the patient is still disease free.

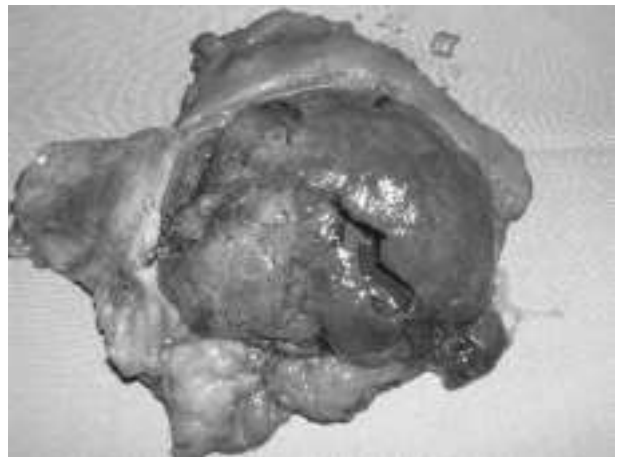


Photo 1. Bladder carcinosarcoma.

Discussion

Carcinosarcoma of the bladder is a rare tumour: less than 50 cases are reported (1). The singleness of the cases doesn't allow a uniformity of therapeutic approach (2). In men it is more frequent than in women with a ratio of 4:1, with greater incidence at the end of the seventh decade of life. Symptoms at pre-

sentation do not differ from those of other bladder cancers (3). A correlation between the onset of the carcinosarcoma and a former therapy with ciclofosfamide has been observed (4) and, according to some Authors, with previous pelvic radiotherapy (2). Professional exposures have been never correlated to this disease (2). Very aggressive behaviour and usually loco-regional extension are the striking features of this neoplasm (5). The most common sarcomatous found elements are condrosarcoma, leiomyosarcoma, fibrosarcoma and rhabdomyosarcoma, while the epithelial components consist of transitional cell carcinoma, small cells carcinoma, squamous carcinoma and other mixed forms (1-6). Macroscopically the carcinosarcoma is a voluminous, bloody, sessil, nodular vegetation; our observation is typical of this disease. The conventional haematoxylin-eosin stain underlines the two components, epithelial and sarcomatous (photo 2).

The epithelial component consists of high grade papillar transitional cell carcinoma with isolated foci of squamous metaplasia.

The sarcomatous component consists of spindle cells proliferation separated one another by an abundant extracellular matrix, with polymorphic and hyperchromic nuclei, prominent nucleoli and many atypical mitotic figures; immunohistochemically the spindle cells react focally with vimentin (photo 3) and smooth muscle actin (photo 4) and are negative for

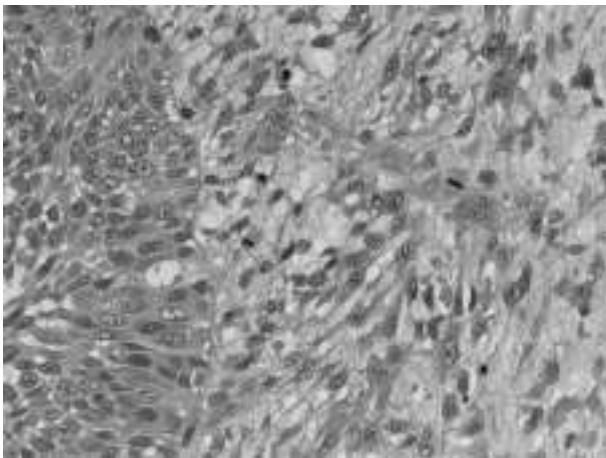


Photo 2. Ematossilina eosina (x20) L'immagine mostra le due componenti quella epiteliale sulla sinistra e quella sarcomatosa sulla destra.

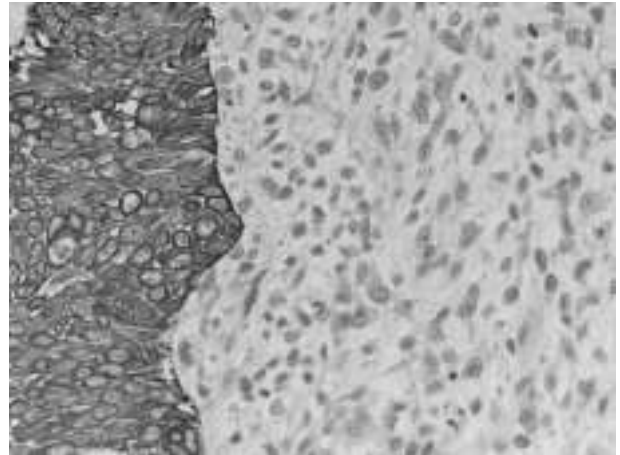


Photo 3. Immunoistochimica anticitocheratine pool (x20) La componente epiteliale reagisce positivamente alla colorazione (paint), mentre la componente sarcomatosa non dipinge

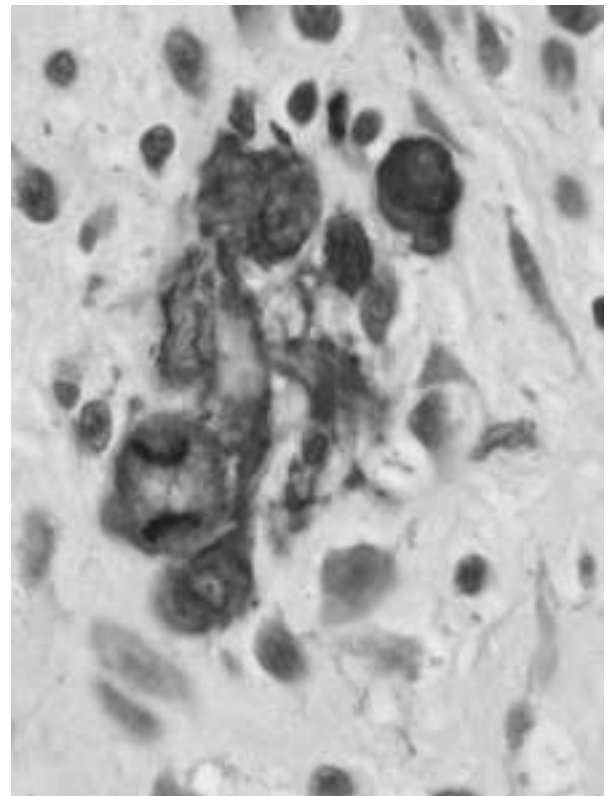


Photo 4. Immunoistochimica anti muscolo liscio (40x) Alcune delle cellule sarcomatose reagiscono positivamente con anti-muscolo liscio.

desmin, S-100, muscle specific actin, CD 31, CD 34, mitogenina and for all the epithelial antigens tested

(cytokeratin pool, EMA, high and low weight cytokeratins). Foci of necrosis and haemorrhage are frequently observed in sarcomatous areas.

Both the components have high proliferative index with Mib-1 (1-6).

The patients affected by carcinosarcoma have a very low survival rate, averaging 17,2 months (2). The treatment of these patients consists of cystectomy or transurethral resection followed in some cases by radiotherapy. Conservative treatment with chemotherapy, proposed by some Authors, has not achieved some substantial improvement (2). There is only a case, in literature, of survival up to 52 months with adjuvant radio and chemotherapy (1).

Conclusions

Carcinosarcoma of the bladder is unusual tumor characterized by admixture of malignant epithelial elements (carcinoma) and malignant tissue elements (sarcoma), that present as high stage malignancies. The symptoms of presentation included hematuria, dysuria and acute urinary retention. The optimal treatment is uncertain, although a small number of patients have experienced prolonged survival with combined surgery and radiation.

This case, beyond the rarity and the histopathologic peculiarity, does not substantially differ from the usual clinical presentation of the most common urothelial neoplasm. We underline the need of precocious diagnosis, in order to perform an early therapeutic ap-

proach that is not different from the usual surgical procedures for the other bladder cancers.

Only future molecular genetic studies may be worthwhile in creating stratification that will be clinically useful for determining treatment or assessing prognosis.

References

1. Torenbeek R, Blomjous CM, de Bruin PC, Newling DWW, Meijer CJLM. Sarcomatoid carcinoma of the urinary bladder. *Amer J Surg Path* 1994; 18: 241.
2. Lopez-Beltran A, Pacelli A, Rothenberg HJ, et al. Carcinosarcoma and sarcomatoid carcinoma of the bladder. *J Urol* 1998; 159 (5): 1497-503.
3. Young RH. Carcinosarcoma of the urinary bladder. *Cancer* 1987; 59: 1333.
4. Sigal SH, Tomaszewski JE, Brooks JJ, Wein A, LiVolsi VA. Carcinosarcoma of bladder following long-term cyclophosphamide therapy. *Arch Path Lab Med* 1991; 115: 1049.
5. Chen KT. Carcinosarcoma of the bladder. Letter to the Editor. *Arch Path Lab Med* 1992; 116: 811.
6. Di Stefano C, Sebastio N, Pozzoli GL, Arena F, Incarbone GP, Cortellini P. Carcinoma sarcomatoide della vescica. *Minerva Urol Nefrol* 1999; 51: 49-51.

Received: 13 January 2003

Accepted in original form: 29 March 2004

Correspondence: Dr. Umberto Maestroni
Azienda Ospedaliera Universitaria di Parma
Unità Operativa di Urologia
Via A. Gramsci, 14
43100 Parma, Italy
Tel: 0521-702381
E-mail: umbe.dana@libero.it