

## Misdiagnosed iuxta-articular osteoid osteoma of the calcaneus following an injury

*Francesco Pogliacomì, Enrico Vaienti*

Section of Orthopaedic, Traumatology and Functional Orthopaedic Rehabilitation, Department of Internal Medicine and Biomedical Sciences, University of Parma, Parma (Italy)

**Abstract.** The diagnosis of osteoid osteoma, in usual localizations, is generally simple. In iuxta-articular localizations this tumor may be unrecognized and the diagnosis delayed. Injury has been sometimes correlated with the onset of symptoms and this can make the diagnosis even more difficult. We present a case of osteoid osteoma of the calcaneus iuxta-articular to the subtalar joint in a 17-year-old basketball player. He had a history of initial injury, ankle sprain during training, followed by pain and swelling. He was initially treated for lateral ligament lesion of the ankle with unsatisfactory results. After acute trauma the pain changed becoming chronic and mostly nocturnal disappearing when rofecoxib was taken. Standard x-ray didn't show the lesion. Nuclear Magnetic Resonance (NMR) and scintigraphic results were not well interpreted but these clinical changes and Computed Tomography (CT) images supported the diagnosis of osteoid osteoma. The complete resection of the bone lesion resolved all the symptoms and the histological report confirmed the suspected diagnosis.

**Key words:** osteoid osteoma, trauma, injury, calcaneus, para-articular and iuxta-articular localization

### Introduction

Osteoid osteoma is a small benign osteoblastic tumor first described by Jaffe (1) in 1935. Among benign tumors of bone, only histiocytic fibromas, exostoses and chondromas are more frequent. It's relatively frequent accounting for 10-15% of all benign bone tumors (2, 3). It usually occurs in the second and third decades of life and men are 2.3 times more affected than women (4).

It's most commonly found in the limbs of the appendicular skeleton, above all in the proximal part of the femur, but it may be seen in any area of the body. In the foot (talus is the preferred location) such tumors are not unusual and the incidence ranges from 4% to 16% (2, 3, 5-8). Talus and calcaneus localizations incidence range respectively from 31% to 59% and from 12,5% to 22% of all reports concerning the foot (6-10).

Although silent and asymptomatic cases have been reported (3, 11, 12) in the typical forms and localizations of the disease the diagnosis is quite simple. In these cases clinical course and radiographic findings, supported by scintigraphic bone scan and CT images, are so typical that diagnosis may be considered certain.

Difficulties in the diagnosis and localization of lesions in the foot are frequent.

Standard x-ray films are often unable to detect the tumor because of the difficulties to point out the lesion in the small tarsal bones.

In joint, periarticular and iuxta-articular localizations, above all in short bones of the foot, the presentation may be different with atypical and nonspecific features and diagnosis may be difficult, uncertain and late (3, 5, 9, 10, 13-15). Clinical symptoms may be very early as compared to radiographic manifestations. Nonspecific pain, stiffness, swelling, effusion, synovi-

tis, muscular atrophy, joint contracture and local warmth may mislead the correct diagnosis. Standard radiographs may at first demonstrate no pathological findings or may show equivocal findings due to the absence of the typical bone modification.

A history of injury preceding the onset of osteoid osteoma has been referred (2, 4, 16-21) and this can make the diagnosis even more difficult, particularly when the symptoms occur soon after injury. In many tumors, injury has been considered as a potential cause. In most cases the correlation between trauma and the onset of the tumor remains unclear.

We report a case of osteoid osteoma in the calcaneus iuxta-articular to the sub-talar joint occurred after an injury (2<sup>nd</sup> grade ankle sprain [22]) which demonstrates how easy is to delay the correct diagnosis and treatment in patients with tumors. This unrecognized osteoid osteoma is the consequence of the low index of suspicion of the physician who preceded the Orthopaedist because of the unusual localization and of the ankle sprain history.

### Case report

A 17 year-old basketball player was referred to our Section in July 2003 with a nine-month history of pain and swelling in the lateral part of his right ankle and foot. The symptoms began after he sprained his ankle during a basketball training in October 2002. He first consulted the physiotherapist of the team and was treated unsuccessfully with elastic functional splint, non-steroidal anti-inflammatory drugs, CO<sub>2</sub> laser, ultrasound and functional rehabilitation therapy.

The patient didn't get any better from this treatment and in December 2002 he consulted the physician of the team. Standard x-ray images were taken at that time showing no signs of bone disease so the patient continued for two weeks a physiotherapeutic treatment with functional rehabilitation and crio-ultrasound.

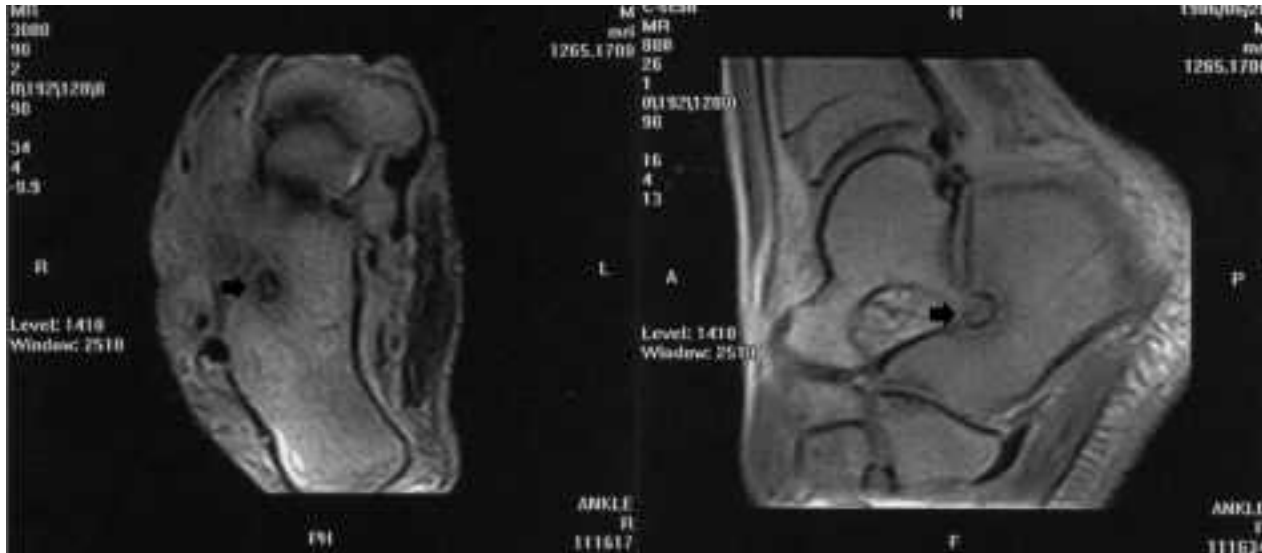
Clinical symptoms and signs improved but didn't heal. In January 2003 the patient tried again to play basketball. Pain features changed becoming chronic and prevalently nocturnal disappearing when rofe-

coxib was taken; digital pressure on "sinus tarsi" evoked a feeling of "prick". Swelling became prevalent after sport activity and disappeared with criotherapy and rest.

He continued basketball activity for 2 months; at the beginning of March 2003 ankle NMR was carried out showing the healed up lesion of the external ligamentous compartment (result of 2<sup>nd</sup> grade ankle sprain) (22) associated with peroneus longus and brevis reactive tenosynovitis and with post-contusive area in the subchondral calcaneal bone just under the subtalar joint (Fig. 1).

In May 2003 bilateral ankle plain radiographs were carried out without pathological bone signs. At the beginning of July 2003 a new NMR showed the same images concerning soft tissues but a bigger post-contusive area in the subchondral calcaneal bone just under the subtalar joint in which a small "focus" of low signal intensity in T1 and T2 weighted images surrounded by a narrow halo of normal intensity was present; in the official radiologist's answer, these NMR images were consistent with "osteomyelitis focus" (Fig. 2).

In the middle of July 2003 he was referred to our Department where a mild swelling all around the lateral malleolus and on the "sinus tarsi" without local signs of infection was observed. Active and passive range of motion were not limited and there was no ankle instability and sensory disturbance. Pain was prevalent and increased at night and disappeared after rofecoxib. The pain was evoked by digital pressure on "sinus tarsi". Routine and inflammatory blood tests and standard x-ray were carried out with results within the reference ranges. Subsequently, the patient underwent isotope bone scan with <sup>99m</sup>Tc that revealed pathologic hyperflow of the radiocompound in the ankle, particularly in the right talus. The static late record revealed a pathologic hyperaccumulation of radiocompound considerable in the right neck talus and mild in the other tarsal bones. These scintigraphic images were consistent, according to the radiologist, with post-traumatic algoneurodistrophy rather than "osteomyelitis focus". Based on the clinical symptoms and because of the different diagnosis suggested by previous investigations, CT scan without contrast medium was done (scansion 10 mm in thickness) showing a rounded (1,28 cm x 0,98 cm) radiolucent area with a small zo-

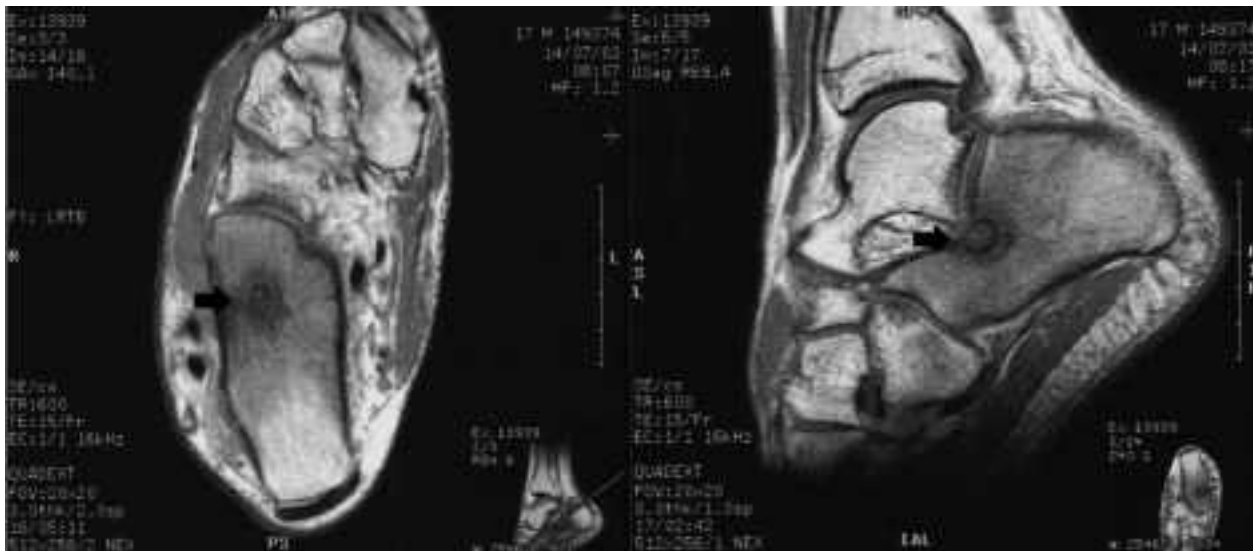


**Figure 1.** March 2003 NMR; rounded image of the calcaneus described as post-contusive area in the subchondral bone just under the subtalar joint (arrows).

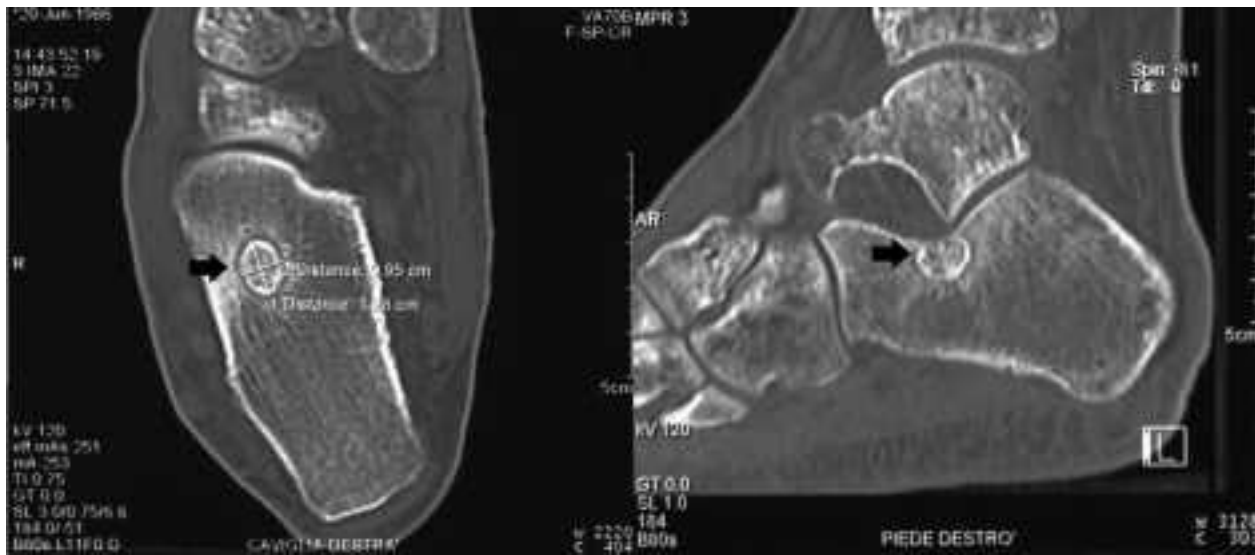
ne of low density signal (nidus) in the centre, surrounded by a halo of bone sclerosis, just under the calcaneal insertion of the interosseous talo-calcaneal ligament (Fig. 3). Finally clinical signs and CT findings directed to the diagnosis of osteoid osteoma.

At the end of July 2003 the patient was operated on by a lateral approach centred on “sinus tarsi”. The

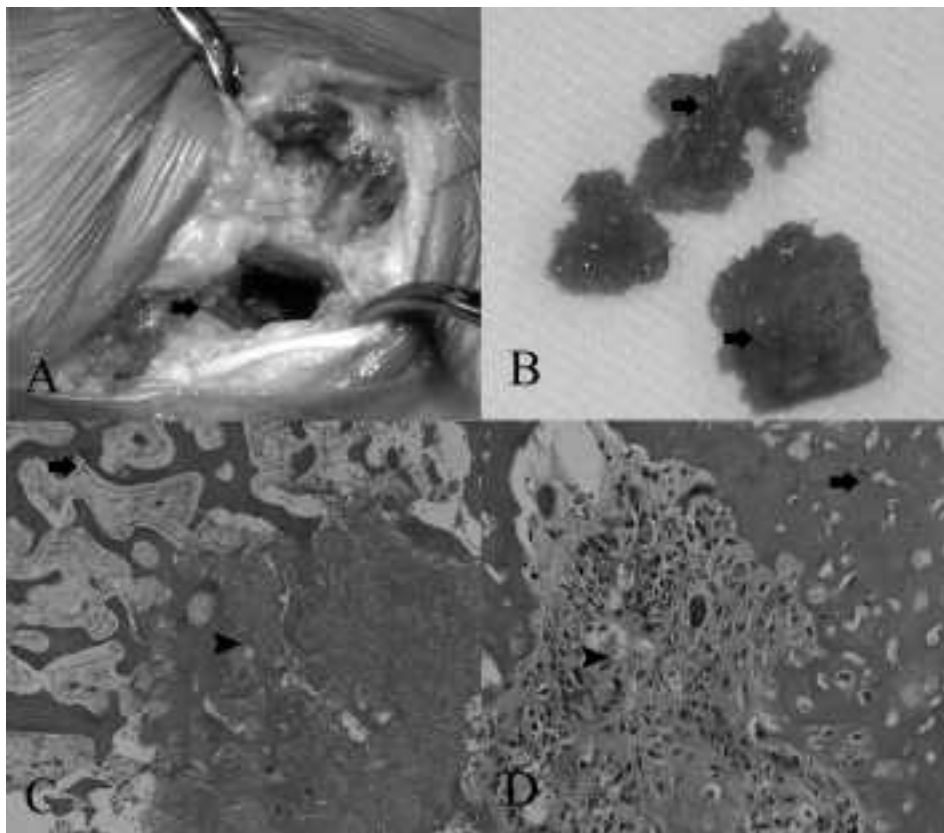
lateral cortical calcaneal bone was resected with an osteotome and the reddish nidus could be seen. Osteoid osteoma was completely excised (Fig. 4A, B) and successive histological examination confirmed the diagnosis (Fig. 4C, D). The pre-operative pain disappeared the same night after the operation and swelling gradually decreased.



**Figure 2.** July 2003 NMR; rounded image of the calcaneus described as post-contusive area in the subchondral bone just under the subtalar joint in which is present a small “focus” of low signal intensity surrounded by a narrow halo of normal intensity interpreted as osteomyelitis focus (arrows).



**Figure 3.** CT scan without contrast medium; rounded radiolucent area with a small zone of low density signal (nidus) in the centre, surrounded by a halo of bone sclerosis (arrows): radiological diagnosis of osteoid osteoma.



**Figure 4.** A) calcaneus after complete resection of the lesion (black arrow). B) bone removed with reddish zone-nidus (black arrow). C) histological examination-medium enlargement. Normal bone tissue (superior arrow) and osteoid tissue (inferior arrow). D) histological examination-maximum enlargement. Normal bone tissue (superior arrow) and osteoid tissue (inferior arrow).

## Discussion

Symptoms and instrumental findings of osteoid osteoma were firstly described by Jaffe in 1935 (1). Although asymptomatic cases have been reported (3, 11, 12), patients usually show well-localized pain with a typical tendency to increase during the night and to relieve with the assumption of salicylates or other non-steroidal anti-inflammatory agents (4, 23).

Although a quarter of osteoid osteoma are not detected on plain radiographs (2, 4, 24), in usual localization the basic radiographic element is a small rounded area of osteolysis ("nidus") surrounded by a ring of bone sclerosis; within this rounded area a central calcific nucleus may be sometimes present. Bone scintigraphy and CT investigation are useful to perform the correct diagnosis, particularly in these small lesions undetected by standard x-rays. Although initial negative isotope bone scan views are reported (2, 25), with the progression of the disease this exam is constantly positive revealing areas of radiocompound hyperaccumulation. CT scan always shows the nidus localization and its size, allowing an adequate and accurate pre-operative planning. NMR study, as well described by Ferrari et al. (13), is less sensitive and specific than CT in determining the nidus; the typical central calcific nucleus is difficult to define and, particularly in iuxta-articular localizations, secondary signs such as reactive synovitis or secondary hyperostosis may be overestimated misdiagnosing the primary tumor.

Although some Authors (2, 26) referred the possibility of symptoms spontaneous resolution with long-term prostaglandin inhibitors therapy (minimum 2 years and often up to 5 years), surgical complete excision is the preferred and definitive treatment with complete and immediate pain relief.

Difficulties and delays in diagnosis of foot osteoid osteoma are common.

Most of the diagnostic problems derive from the atypical roentgenographic findings. The x-ray record of osteoid osteoma in the foot is more difficult because of the higher incidence of infraspongious and iuxta-articular localizations which are not so characteristic as the intracortical forms. In the infraspongious types the lesion is particularly small and the reaction

of the surrounding bone is not well-defined without reactive sclerosis. In iuxta-articular types clinical symptoms may be very early as compared to radiographic signs and inflammatory arthritis may be suspected instead of osteoid osteoma.

A history of trauma preceding the onset of osteoid osteoma has been described (2, 4, 16-18, 20, 21, 24, 27); this can mislead the correct diagnosis, particularly if symptomatology begins soon after the injury. Uda et al. (4) misdiagnosed an osteoid osteoma as post-traumatic periostitis and Trettin et al. (2) misdiagnosed this lesion as chronic capsular strain. An association between trauma and the onset of the tumor is not clear. Formerly Jaffe (1) and more recently Carroll (28) postulated that this neoplasma is not related to trauma. Baron et al. (20) speculated that post-traumatic haematoma or intervention of osteoid tissue at the time of an operation may cause the lesion. Spjut et al. (29) postulated that the development of the nidus and disappearance of the old bone are consequences of vascularization problems. Adil et al. (16) in his post-fracture case report supposed that fracture and internal fixation may have acted as a trigger for osteoid osteoma formation and particularly the invagination of the periosteum at the time of reduction and fixation caused the lesion.

In our case report foot iuxta-articular localization, previous trauma, low index of suspicion of the physicians who initially investigated and treated the patient, misled and delayed the correct diagnosis.

When the patient was referred to our Department his symptoms and their regression after rofecoxib administration and CT scan images were characteristic of osteoid osteoma. The history of ankle sprain, the short time between the appearance of the suggestive pain and trauma and the non-evident lesion in standard x-ray didn't help the physician who first treated the patient. The first NMR carried out wasn't significant. The second NMR suggested a diagnosis of osteomyelitis focus. Furthermore isotope bone scan report suggested post-traumatic algoneurodystrophy rather than osteomyelitis. We excluded the hypothesis of osteomyelitis because there were no symptoms and signs of localized infection and inflammatory blood tests were within the normal range. No wound and no surgical procedure in the ankle fol-

lowed traumatic event. Clinical (characteristic of pain) and x-ray features in the ankle (absence of tarsal demineralization) removed the suspect of algoneurodystrophy. The correct diagnosis was confirmed by symptoms resolution after surgical excision and by histological examination.

We didn't establish a clear association between trauma and the onset of osteoid osteoma. Because of the absence of an examination before trauma it was impossible to say if the lesion existed already before the injury or it occurred accidentally after trauma. We supposed that ankle sprain may have acted as trigger and activated a silent tumor already present. As well described in literature (23, 30, 31), nidus contains an abnormally high quantity of prostaglandins, which are considered to be related to the pain. In this case osteoid osteoma was localized in the calcaneus just under the calcaneal insertion of the interosseous talocalcaneal ligament. Ankle sprain and interosseous ligament straining may have caused micro-lesion of the bone all around the silent lesion and, with the high vascularity which followed the injury and physiotherapeutic treatment, may have supported an increased production and release of prostaglandins and other pain mediators.

This case report wants to emphasize that osteoid osteomas of the foot are difficult to diagnose and a history of trauma preceding the onset of symptoms can make the diagnosis even more difficult. X-ray standard images and CT scans may direct the diagnosis. Clinical features are in this tumor suggestive and unique. When a patient reports a history of trauma followed by pain which changes becoming nocturnal, disappearing with non-steroidal anti-inflammatory agents administration, it is important to include osteoid osteoma as a differential diagnosis.

## References

- Jaffe HL. Osteoid osteoma: a benign osteoblastic tumor composed of osteoid and atypical bone. *Arch Surg* 1935; 31: 709-28.
- Trettin DM, Browne JE. Osteoid osteoma of the tarsal cuboid presenting with recurrent ankle sprains in an adolescent: a case report. *Foot Ankle* 1995; 16: 30-3.
- Temple HT, Tuyethda NV, Mizel M. Intra-articular osteoid osteoma as a cause of chronic ankle pain. *Foot Ankle Int* 1998; 19 (6): 384-7.
- Uda H, Mizuzeki T, Tsuge K. Osteoid osteoma of the metacarpal bone presenting after an injury. *Scand J Plast Reconstr Surg Hand Surg* 2002; 36 (4): 238-42.
- Barca F, Leti Acciaro A, Spina V. Intra-articular osteoid osteoma of the lower extremity: diagnostic problems. *Foot Ankle Int* 2002; 23 (3): 264-7.
- Capanna R, Bettelli G, Ruggieri P, Biagini R, Giunti A. Osteomi osteoidi del piede. *Chir Organi Mov* 1986; 72: 195-201.
- Freiberg RH, Loitman BS, Helpert N. Osteoid-osteoma. A report on 80 cases. *AJR Am J Roentgenol* 1959; 82: 284-5.
- Lejeune E, Dejour H, Bouvier M, Andr -Fouet A. L'ost eome ost oide du pied. Apropos de quatre observations personnelles. *Rev Rhum* 1979; 46: 711-7.
- Resnick RB, Kenneth LJ, Shesker SC, Panna Desai, Cisa J. Arthroscopic removal of an osteoid osteoma of the talus: a case report. *Foot Ankle Int* 1995; 16(4): 212-5.
- Shereff MJ, Cullivan WT, Johnson KA. Osteoid osteoma of the foot. *J Bone and Joint Surg* 1983; 65 A: 638-41.
- Lawrie TR, Aterman K, Sinclair AM. Painless osteoid osteoma: a report of two cases. *J Bone and Joint Surg* 1970; 52 A: 1357-63.
- Sevitt S, Horn JS. A painless and calcified osteoid osteoma of the little finger. *J Pathol* 1954; 67: 571-4.
- Ferrari D, Tigani D, Busacca M, Rimondi E, Giunti A. Osteoid osteoma: diagnostic problems in joint and periarticular localizations. *Chir Organi Mov* 1999; 84 (2): 171-7.
- Torg JS, Loughran T, Pavlov H, et al. Osteoid osteoma. Distant, periarticular, and subarticular lesions as a cause of knee pain. *Sports Med* 1985; 2 (4): 296-304.
- Negri N, Nurra A, Vaienti E. Rigidit  del gomito da osteoma osteoide della fossa olecranicca. *Chir Organi Mov* 1987; 72 (3): 295-8.
- Adil A, Hoeffel C, Fikry T. Osteoid osteoma after a fracture of the distal radius. *AJR Am J Roentgenol* 1996; 167 (1): 145-6.
- Garcia G, Lance JF, Lin JJ. Osteoid osteoma: an unusual presentation. *Clin Orthop* 1981; 156: 216-8.
- Leonhardt J, Bastian L, Rosenthal H, Laenger F, Wippermann B. Post-traumatic osteoid osteoma. Case report and review of the literature. *Unfallchirurg* 2001; 104 (6): 553-6.
- Rotzer A, Umbricht R, von Wartburg U. Post-traumatic osteoid osteoma of the hand. A rare cause of chronic pain. Case report and review of the literature. *Handchir Mikrochir Plast Chir* 1998; 30 (5): 335-7.
- Baron D, Soulier C, Kermabon C, Leroy JP, Le Goff P. Post-traumatic osteoid osteoma. Apropos of 2 cases and review of the literature. *Rev Rhum Mal Osteoartic* 1992; 59 (4): 271-5.
- Ambrosia JM, Kernek CB. Osteoid osteoma of the foot: presentation following trauma. *Orthopedics* 1985; 8(5): 684-5.
- Lanzetta A. Le lesioni capsulo-legamentose della caviglia nella traumatologia sportiva. "Ciba-Geigy-Milano", 1991, 33.

23. Healey JH, Ghelman B. Osteoid osteoma and osteoblastoma: current concepts and recent advances. *Clin Orthop* 1986; 204: 76-85.
24. Bednar MS, McCormack RR Jr, Glasser D, Weiland AJ. Osteoid osteoma of the upper extremity. *J Hand Surg* 1993; 18A: 1019-25.
25. Kaweblum M. Diagnosis of osteoid osteoma in the child. *Orthop Rev* 1993; 12: 1305-13.
26. Jackson RP, Reckling FW, Mantz FA. Osteoid osteoma and osteoblastoma: similar histologic evaluations with different natural histories. *Clin Orthop* 1977; 128: 303-13.
27. Kendrick JI, Evarts CM. Osteoid-osteoma: a critical analysis of 40 tumors. *Clin Orthop* 1967; 54: 51-9.
28. Carroll RE. Osteoid osteoma in the hand. *J Bone and Joint Surg* 1953; 35A: 888-93.
29. Spjut HJ, Fechner RE, Ackerman LV. Tumors of bone and cartilage, fasc. 5. Washington DC: Armed Forces Institute of Pathology, 1971: 120-32.
30. Makely J. Prostaglandins-A mechanism for pain mediation in osteoid osteoma. *Orthop Trans* 1982; 6: 72.
31. Campanacci M. Bone and soft tissue tumors (2nd edition). Piccin Nuova Libreria Padova. 1999: 407.

---

Received: 23 September 2003

Accepted in original form: 26 October 2003

Correspondence: Francesco Pogliacomì, MD

Section of Orthopaedic, Traumatology and

Functional Orthopaedic Rehabilitation

Department of Internal Medicine and Biomedical Sciences

University of Parma, Parma Hospital

Via Gramsci 14,

43100 Parma, Italy

Tel: 0521-702144/ 290439

Fax: 0521-290439

E-mail: fpogliacomì@yahoo.com