

Rehabilitation experience in a case of Ollier's disease

Alberto Formis¹, Stefania Allegri², Lucio Posteraro²

¹Post Graduate Medical School in Physical Medicine and Rehabilitation, University of Parma, Italy; ²Rehabilitation Unit of Bozzolo, Mantova Hospital, Bozzolo, Italy

Abstract. This paper describes a case of Ollier's disease, an uncommon, nonhereditary skeletal disorder affecting enchondral ossification. The patient was referred to our Rehabilitation Unit after resection of scapular chondroma. He had previously been submitted to several surgical treatments for multiple enchondromatosis. Rehabilitation goals were increasing range of motion, relieving pain and training activities of daily living (ADL). After one month treatment, the patient reported pain relief and showed good improvement of articular function and better performances on ADL. According to our experience, it seems that rehabilitation could play a complementary role as regards surgical treatment of this complex pathology.

Key words: Ollier's disease, rehabilitation

Introduction

Ollier's disease is an uncommon, nonhereditary skeletal disorder of enchondral ossification (1-3), characterized by persisting cartilage masses in the metaphysis and diaphysis, subperiosteal deposition of cartilage and asymmetrical involvement of the limbs. The affected bones are often shortened and deformed. In childhood they are subject to pathological fractures and in adult life to malignant degeneration (4). An association with brain tumors is also described (5-7).

This disorder is called Maffucci's syndrome when it is associated with skin angiomas (Maffucci, 1881).

The first case was described in 1897 by Louis Xavier Edouard Léopold Ollier (1830-1900), the father of the orthopedic surgery, during a Meeting of the Lyon Surgical Society (8). The patient was a 6 year-old child with deformity to a forearm and tibia and multiple finger swellings. Ollier then described a 9 year-old patient with involvement of the long bones (9).

The classification of multiple enchondromatosis is still debated. Spranger and coworkers (10) distinguish six types of enchondromatosis.

- Ollier's disease, sporadic form (type 1);
- Maffucci's syndrome, sporadic form with skin angiomas (type 2);
- metaphysal chondromatosis, autosomal form with esostosis (type 3);
- spondylenchondrodisplasia, recessive autosomal form with generalized platyspondylia (type 4);
- enchondromatosis with vertebral lesions (type 5);
- sporadic generalized enchondromatosis (type 6).

Ollier's disease is usually surgically treated, considering the high frequency of malignant evolution of the lesions (11-15), even though tumors are often benign. In case of malignant evolution radiotherapy and/or chemotherapy are requested (16). Relapses are frequent (25-50%).

To date the role of rehabilitation in the treatment of multiple enchondromatosis is not clear. To our knowledge in literature there are no studies on rehabilitative management of these patients in conjunction with surgical treatment. The aim of this paper is to describe the effects of rehabilitative treatment for a case of Ollier's disease.

Case report

NV, was a 32 years old man; telephone operator.

– *Medical history:* his brother is affected by multiple chondromas of the fingers. When NV was 5 years old, he was recognized to be affected by Ollier's disease. Subsequently the patient underwent 18 surgical procedures for several bone lesions.

The patient was referred to our Rehabilitation Unit after right subtotal scapulectomy. On admission he complained headache, chronic low back pain increased after back extension, poor mobility of the right shoulder, general weakness with autonomy reduction in activities of daily living (ADL). The patient was under high doses of analgesic drugs (diclofenac 150 mg daily).

– *General examination:* height 168 cm, weight 74,5 Kg, coarse facies, dorsal kyphosis, low limb/trunk ratio. In particular, relative shortening of the arm compared to forearm was observed (Figure 1a).




Figure 1a. Arm/forearm ratio

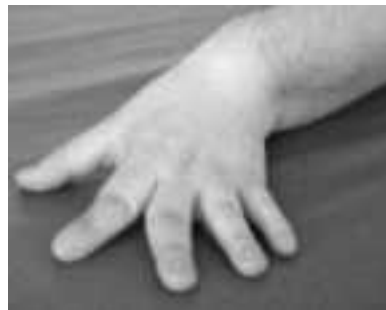

Figure 1b. Left hand

Bilateral coxa vara was present. Lower limbs were asymmetrical, since right femur was 2 cm shorter than left one. Femur/tibia ratio was abnormal. Left hand showed angular deformities of 2nd and 3rd axes (Figure 1b).

Multiple swellings near the joints, bilateral genu valgum, flat feet were showed. Lower limbs were hypotrophic and weak. The patient demonstrated poor stability in stance. He walked with a limp due to limb-length discrepancy.

– *Joint assessment:*

Spine: restricted mobility was for all directions.

Shoulders: poor abduction (left 120° - right 110°) and active rotation (Figure 1c).

Elbows: limited extension, normal flexion (right 160°, 40°; left 150°, 45°).

Hip: limited internal rotation (left 50° - right 45°).

Knee: limited flexion (right 80° - left 65°).

Ankle: limited dorsal-flexion (right 90° - left 110°) (Figure 3).

– *Radiographic findings:* multiple chondromas localized at proximal and distal epiphysis of femur, tibia, fibula, humerus. Bilateral coxa vara with deformity of proximal epiphysis of femur; deformity of humerus and left scapula, multiple swellings of toracic cage (Figures 2-5).

– *Neuropsychological examination:* the patient was alert, cooperative and well oriented. His spontaneous speech was fluent without structural abnormalities. Verbal comprehension was normal. On Raven's Progressive Matrices 38 the patient's score was 31/48; this value is located between 10th and 25th percentiles of normal subjects.

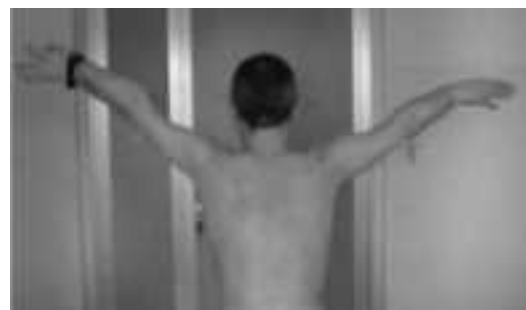

Figure 1c. Shoulder abduction

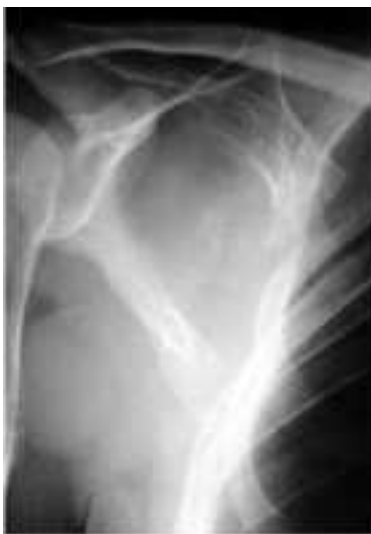

Figure 2a. Right shoulder

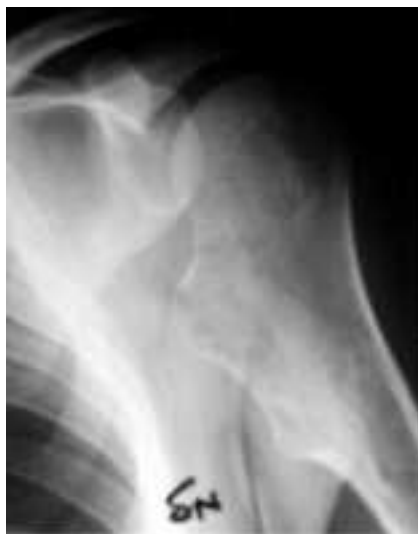

Figure 2b. Left shoulder

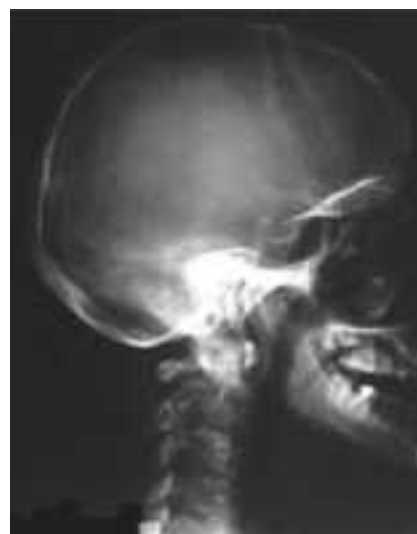

Figure 3. Skull

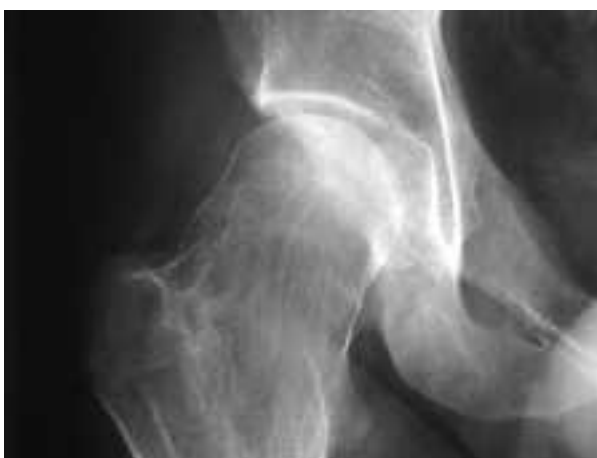

Figure 4a. Right hip

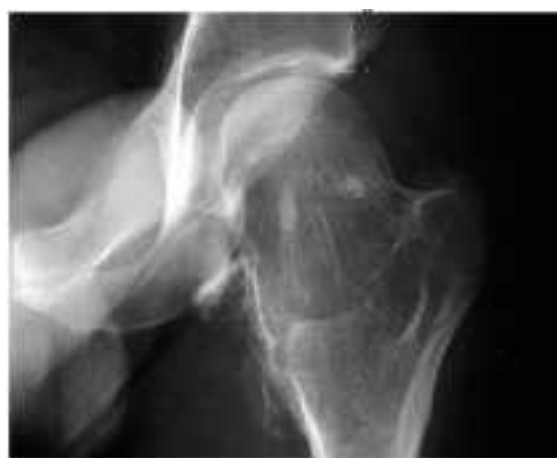

Figure 4b. Left hip

– *Quantitative assessment:* both on admission and at discharge N.V. underwent the following tests:

- Visual Analogue Scale (V.A.S.) (17)
- The Short – Form – 36 Health Status Survey (SF-36) (18)
- Functional Independence Measures (FIM) (19)

– *Rehabilitation treatment:* major targets of rehabilitation program were: to relieve pain, to increase range of motion and strength. For this purpose the patient took analgesic drugs, and underwent physical therapy (ultrasound, criotherapy, CO₂-laser) and physiotherapy (15 sessions of 45 minutes each) with stret-

ching, active mobilization, “back school”, occupational therapy and coordination exercises.

Rehabilitation treatment lasted one month.

Results

During his stay at our Rehabilitation Unit the patient had a regular clinical course. At discharge he reported pain relief. Dosage of analgesic drugs was significantly reduced.

Muscular strength and resistance increased.

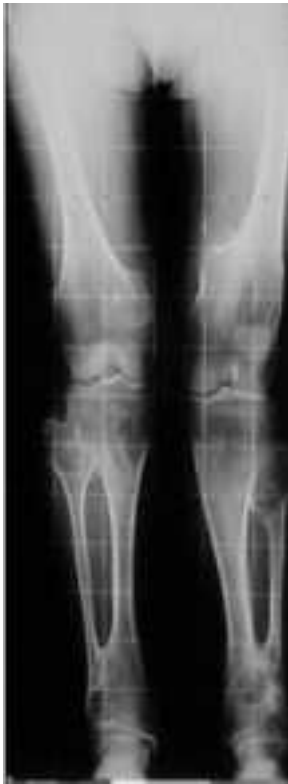

Figure 5a. Lower limbs

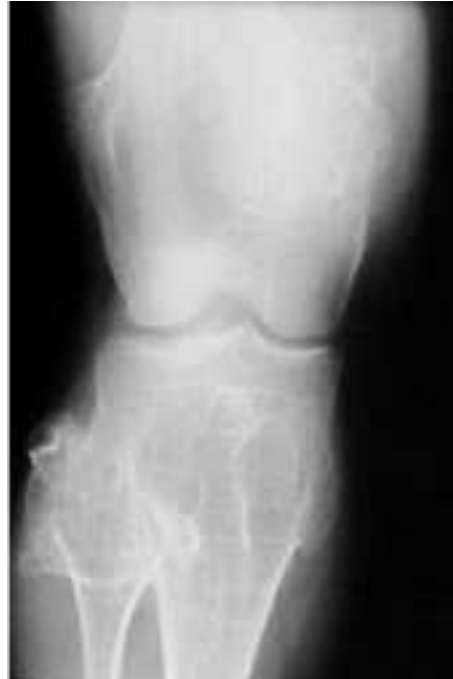

Figure 5b. Right knee

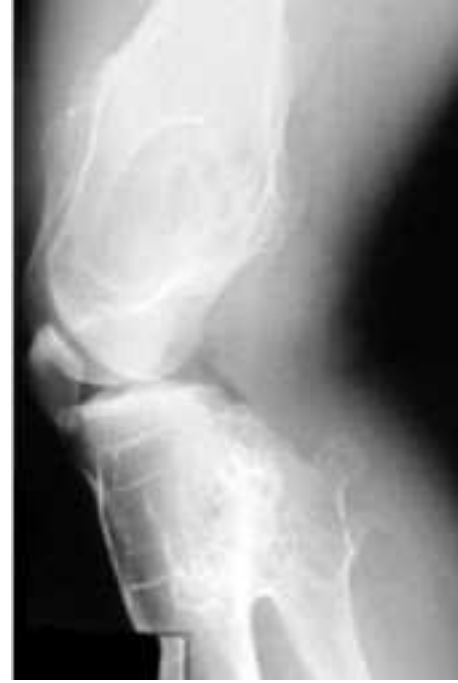

Figure 5c. Left knee

Furthermore the range of motion at discharge was better for all joints than at outset. In particular right shoulder abduction became normal.

Quantitative assessment showed an overall improvement (Table 1 and Figure 6).

Table 1.

| | Admission | Discharge |
|------------------------------|-----------|-----------|
| <i>A: SF- 36 scores</i> | | |
| Physical Activity (PA) | 87% | 95% |
| Role of Physical Health (RP) | 25% | 100% |
| Physical Pain (PP) | 21% | 73% |
| General Health (GH) | 66% | 61% |
| Vitality (VT) | 25% | 90% |
| Social Activity (SA) | 12% | 75% |
| Humor (HU) | 0% | 100% |
| Mental State (MS) | 44% | 64% |
| <i>B: FIM scores</i> | | |
| FIM | 71 | 92 |
| <i>C: VAS scores</i> | | |
| VAS | 5 | 1.5 |




Figure 6. SF 36 scores

Conclusion

This case report highlights that good results may be obtained in a patient with Ollier's disease thanks to the rehabilitation treatment. Surgery is usually the only treatment considered for this disorder. As far as we know no studies on effects of rehabilitation for Ollier's disease have been already reported.

This lack could be due to:

- Ollier's disease shows itself under different clinical forms which need different surgical treatments;
- it is difficult to enrol a significant sample of patients homogeneous according to disabilities.

Our experience has demonstrated that rehabilitation could be an useful integration of surgical treatment in this disease, as well as for other orthopaedic diseases. Unfortunately data regarding follow-up of our patient are lacking.

In this regard, the patient has recently reported that he had to perform diagnostic procedure (angiography) for chondroma located at right forearm. Further surgical intervention will be then possible.

It is hopeful that in the future more rehabilitation studies on patients suffering from Ollier's disease will be performed.

Furthermore it must be outlined that continuous follow-up is very important for this kind of disorder, even to clarify long term results of rehabilitation. From this point of view, we agree with previous reports of literature (20).

References

1. Ozisik YY, Meloni AM, Spanier SS, Bush CH, Kingsley KL, Sandberg AA. Deletion 1p in a low-grade chondrosarcoma in a patient with Ollier's disease. *Cancer Genet Cytogenet* 1998; 105 (2): 128-33.
2. Schwartz HS, Zimmerman NB, Simon MA, Wroble RR, Millar EA, Bonfiglio M. The malignant potential of enchondromatosis. *J Bone Joint Surg Am* 1987; 69 (2): 269-74.
3. Shapiro F. Ollier's Disease. An assessment of angular deformity, shortening and pathological fracture in twenty-one patients. *J Bone Joint Surg Am* 1982; 64 (1): 95-103.
4. Clavert P, Bonnomet F, Gicquel P, Lefebvre Y, Babin S, Kempf JF. Bilateral subtotal scapulectomy for chondrosarcoma in Ollier's disease within a 16-year interval. *Rev Chir Orthop Reparatrice Appar Mot* 2001; 87 (3): 281-5.
5. Balcer LJ, Galetta SL, Cornblath WT, Liu GT. Neuroophthalmologic manifestations of Maffucci's syndrome and Ollier's disease. *J Neuroophthalmol* 1999; 19 (1): 62-6.
6. Hofman S, Heeg M, Klein JP, Krikke AP. Simultaneous occurrence of a supra- and an infratentorial glioma in a patient with Ollier's disease: more evidence for non-mesodermal tumor predisposition in multiple enchondromatosis. *Skeletal Radiol* 1998; 27 (12): 688-91.
7. Van Nielen KM, De Jong BM. A case of Ollier's disease associated with two intracerebral low-grade gliomas. *Clin Neurol Neurosurg* 1999; 101 (2): 106-10.
8. Ollier M. De la dyscondroplasie. *Bull Soc Chir: Lyon* 1899; 3, 22-27.
9. De Mourges G. Leopold Ollier (1830-1900) Père de la Chirurgie Orthopedique. *Rev Clin Orthoped* 1979; 65-25.
10. Spranger J, Kemperdieck H, Bakowski H, Opitz JM. Two peculiar types of enchondromatosis. *Pediatr Radiol* 1978; 7 (4): 215-9.
11. Bovee JV, Van Roggen JF, Cleton-Jansen AM, Taminiu AH, Van Der Woude HJ, Hogendoorn PC. Malignant progression in multiple enchondromatosis (Ollier's disease): an autopsy-based molecular genetic study. *Hum Pathol* 2000; 31 (10): 1299-303.
12. Braddock GTR, Hadlow VD. Osteosarcoma in enchondromatosis (Ollier's disease.). Report of a case. *J Bone Joint Surg* 1966; 48 B (1): 145-9.
13. Cannon SR, Sweetnam DR. Multiple chondrosarcomas in dyschondrodisplasia (Ollier's disease). *Cancer* 1985; 15; 55 (4): 836-40.
14. Schaison F, Anract P, Coste F, De Pinieux G, Forest M, Tomeno B. Chondrosarcoma secondary to multiple cartilage diseases. Study of 29 clinical cases and review of the literature. *Rev Chir Orthop Reparatrice Appar Mot* 1999; 85 (8): 834-45.
15. Schwarz W, Harges J, Schulte M. Multiple enchondromatosis: Ollier's disease. *Unfallchirurg* 2002; 105 (12): 1139-42.
16. Hasbini A, Lartigau E, Le Pechoux C, Acharki A, Vanel D, Genin J, Le Cesne A. Chondrosarcoma in Ollier's disease. Apropos of 2 cases and review of the literature. *Cancer Radiother* 1998; 2 (4): 387-91.
17. Downie WW, Leatham PA, Rhind VM, Wright V, Branco JA, Anderson JA. Studies with pain rating scales. *Ann Rheum Dis* 1978; 37: 378-81.
18. Ware JE, et al. SF-36 Health Survey: manual and interpretation guide. Boston, Massachusetts: The Health Institute, New England Medical Center, 1993.

19. Hamilton BB, Fuhrer MJ (Eds) In: "Rehabilitation Outcomes: Analysis and Measurement". Baltimore: Brooks 1987; 137-47.
20. Kozłowski KS, Masel J. Distinctive enchondromatosis with spine abnormality, regressive lesions, short stature, and coxa vara: importance of long-term follow-up. *Am J Med Genet* 2002; 107 (3): 227-32.

Received: 14 April 2003

Accepted in original form: 23 June 2003

Correspondence: Lucio Posteraro M.D.

Rehabilitation Unit of Bozzolo

Mantova Hospital

Via 25 Aprile 71

46012 Bozzolo, Mantova, Italy

Tel: 0376/909371

E-mail: luposter@tin.it