

Giant metastatic small bowel and mesentery localization and pleural metastases secondary to breast cancer. Case report

Berardo De Berardis, Guido Torresini, Splendorina Marinelli, Maurizio Brocchi, Roberto Crisci**

Department of Surgical Semeiotic – University of L'Aquila – Hospital of Teramo – Italy

* Department of Thoracic Surgery – University of L'Aquila – Hospital of Teramo - Italy

Abstract. The authors present a case of a patient with double metastatic abdominal and thoracic localization coming from breast cancer. Peculiarity of this case concerns both the considerable size of metastatic abdominal mass (11 centimetres of the major axis for a weight of almost half a kilogramme) and the swift development of the relapses at distance, even in the presence of an original tumour at first stage. Both abdominal surgical operation of the removal of the mass and diagnostic video assisted thoracoscopy (VAT) are described.

Key words: breast carcinoma metastases, pleural metastases

Introduction

Metastases from breast carcinoma are relatively common and can precociously show themselves, but even at distance of many years from the original tumour.

The most common metastatic localizations concern bones and liver, but other localizations can be present in many other organs and apparatus, even if in a smaller percentage.

The Authors relate an exceptional case of a patient (58 years old) who first presented, after 6 months from the operation of radical right mastectomy for breast carcinoma, a giant metastasis on the mesentery and then, after 2 months, an omolateral pleural effusion with diffused pleural metastases.

Case report

The patient, P.E. female, 58 years old, was admitted in our Department to undergo an operation

for right mammary neoplasm (about 4 centimetres) appeared 6 months before. Histological examination performed during the operation showed the presence of "intraductal carcinoma" and therefore radical right mastectomy was performed with omolateral complete axillary lymphadenectomy. Final histological examination attested the intra-operating datum, without the metastatic implication of axillary lymph-nodes and besides the estrogens receptors of the tumour resulted positive for the 80%; on the basis of these data the final staging of the breast cancer was: T2-N0-M0. The patient was discharged from hospital in seventh day in very good conditions and, according to protocol, she underwent a therapy with tamoxifen and a chemotherapy in an oncological centre

About 6 months later, the patient came back to our observation complaining a sharp abdominal pain localized in the para-umbilical area irradiated on the right side; the objective examination showed the presence of a big roundish mass, palpable between right hypocondrium and right iliac fossa, just a little floating with a density in appearance hard-parenchy-

matous; the patient didn't present either disorders of the digestive tract or womb's alteration.

For the reasons given above, the patient was admitted into hospital and submitted to many different diagnostic examinations. The abdominal echography and the thoracic-abdominal CT showed the presence of a big mass with a parenchymatous density, as a voluminous orange, apparently contacting with the small bowel's loops and with the mesentery root, without infiltrating aspects in the other surrounding organs; the bone scintigraphy and the pancolonscopy were negative.

Therefore the patient underwent surgical operation; after a xifo-umbilical laparotomy and opening of peritoneum, a mass of about 10 centimetres (Fig. 1) was immediately localized, whitish hard and bumpy, beginning from the root of the mesentery contacting with some loops of the jejunum and with some mesenteric vessels. Then the mass including the mesentery, 50 centimetres of small bowel in contact with the neoplasm and some para-mesenteric lymph-nodes with increased dimensions, was removed (Figg. 2, 3); therefore an end-to-end jejunal anastomosis with double layer was performed.

At the histological macroscopic examination the mass measured 11 centimetres of diameter with a weight of 480 grams, while at the histological microscopic examination this mass was referable to a carcinomatous not much differentiated process with a vaguely "cordoned" structure compatible with

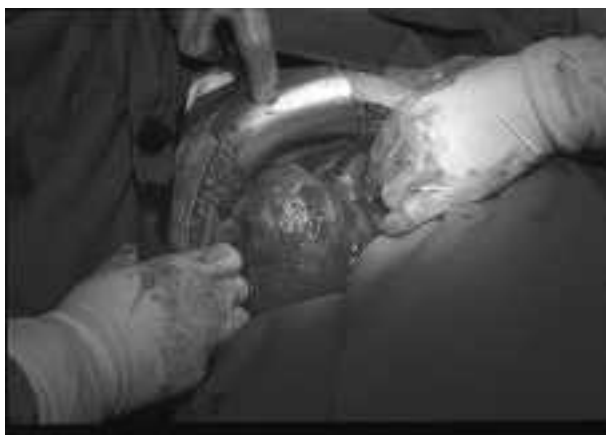

Figure 1. Immediately singling out of the mass after laparotomy

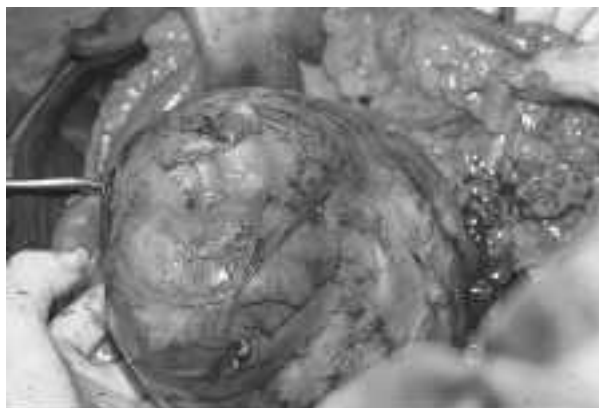


Figure 2. Enucleation of the mass from the abdomen

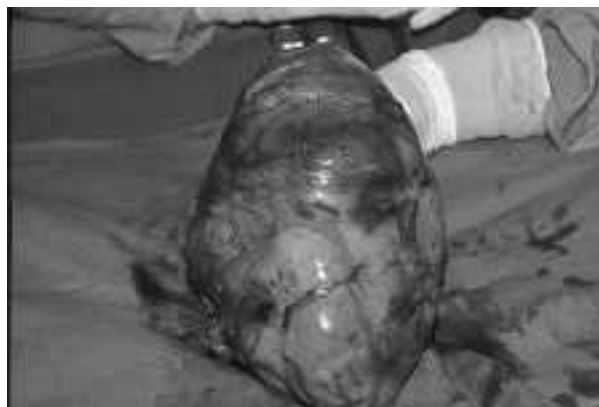

Figure 3. The removed giant metastasis

metastatic lymph-nodal relapse in the mesenteric tissue from mammary gland's carcinoma; also the lymph-nodes founded in peri-intestinal area seemed totally substituted by the above-named neoplastic tissue; but the mucosa of the jejunal specimen didn't show any alteration of neoplastic nature.

The patient was discharged from hospital in tenth day in good conditions, with the advice to continue the chemotherapeutic treatment started months with a careful diagnostic follow-up.

About 3 months later, the patient came back to the hospital, for the beginning of a dyspnoea caused by the presence of a remarkable pleural effusion omolateral to the operation of previous mastectomy. The thoracentesis showed the presence of a citrine-opaque liquid, while the cytological examination confirmed the presence of many carcinomatous cells; the thorax

CT confirmed of a plentiful effusion, while other diagnostic examinations (bone scintigraphy, abdomen CT) excluded new neoplastic localizations.

At this point, for a correct diagnosis, the patient underwent diagnostic videothoracoscopy (VAT) with general anaesthesia: subject introduction of trocar in the 6th right intercostals space on middle axillary line and careful aspiration of the pleural effusion, the thoracoscope showed a probable micro-nodular metastatic whitish diffusion on visceral and parietal pleura, on which many and plentiful biopsies were effected. In this situation, an immediate intrathoracic chemical pleural adhesion with sterile talc was also effected, useful to stick visceral and parietal pleura, so avoiding the relapses of pleural diffusion; the VAT was ended with the placement of pleural drainage 36 Ch in continue aspiration.

The final histological examination confirmed multiple metastatic relapses compatible with breast cancer.

The patient was discharged from hospital in sixth day in ordinary condition; at present, after 3 months from last operation she's continuing the chemotherapeutic treatment in stationary conditions.

Discussion and conclusions

The breast carcinoma is certainly one of the most common tumours in women.

The high mortality that this kind of tumour roused until about 10 years ago is certainly now reduced, thanks to the best health culture of the modern society to the extraordinary development of the diagnostic-therapeutic techniques in the last years.

For all that above mentioned, the breast carcinoma as well the growth of its metastases continue to be aggressive and common also in women who executed anti-estrogens therapy and chemotherapy before and after surgical operation.

The distance metastases of breast carcinoma concern especially liver (1) and bone, but other organs can be struck, even if in a lower percentage, such as stomach, peritoneum (2) and retro-peritoneum (3), mesenteric lymph-nodes, the genito-urinary tract, pleura and, much more rarely, soft tissues.

According to C. Caskey (4), who very carefully analysed the frequency and distribution of extra-skeleton and extra-hepatic metastases in patients with breast cancer, it is clear that the mesenteric lymph-nodes metastases are present in the 3.8% of the cases examined, with dimensions that don't go beyond 2-3 centimetres, while pleural and diaphragmatic metastases are present in the 0.8%.

These data confirm the peculiarity of the presented clinical case, in which, besides the uncommonness of the dimensional datum of metastasis (11 centimetres of greater axis), even both localizations showed themselves after a short time.

The description of this clinical case externally emphasizes two kinds of problems.

First, the establishment of a multiple metastatic process after a short time from the resection of the primary tumour, also if at first stage: this aspect suggests how much it is important to establish a protocol useful to show possible sentinel lymph-node (5) and also a neoadjuvant and post-surgical chemotherapeutic and/or hormonal protocol, according to the oncologist, confirming that the therapeutic treatment of these tumours presents better results when it is "multimodal".

Secondly, the almost absolute absence of symptoms in the patient in spite of the enormous dimensions of neoplastic abdominal mass: this aspect obliges to practise in these women a careful, complete and periodical diagnostic-instrumental follow-up, even if the patient appears in good general condition or she is submitted to the chemotherapeutic and/or hormonal treatment.

A "multi-specialistic" approach is a determining factor for the treatment of these tumours, in the interest of the patients.

References

1. Carlini M, Lonardo MT, Carboni F, Petric M, Vitucci C, Santoro R, Lepiane P, Ettorre GM, Santoro E. Liver metastases from breast cancer. Results of surgical resection. *Hepatogastroenterology* 2002; 49 (48): 1597-601.
2. Hawes D, Robinson R, Wira R. Pseudomyxoma peritonei from metastatic colloid carcinoma of the breast. *Gastrointest Radiol* 1991; 16: 80-2.

3. Carloss H, Saab G. Breast cancer and retroperitoneal metastasis. *South Med J* 1981; 73: 1570-1.
4. Caskey CI, Scatarige JC, Fishman EK. Distribution of metastases in breast carcinoma: CT evaluation of the abdomen. *Clinical Imaging* 1991; 15: 166-71.
5. Rutgens E, Niewey O. Finding lymph-node metastases in invasive breast cancer; sampling or sentinel node procedure? *Eur J Surg Oncol* 2002; 28(6): 569.

Received: 10 January 2003

Accepted after revision: 5 June 2003

Correspondence: Guido Torresini

Via Battistelli, 5

64100 Teramo - Italy

E-mail: gutor@virgilio.it